ATLAS OF MEDICAL PARASITOLOGY

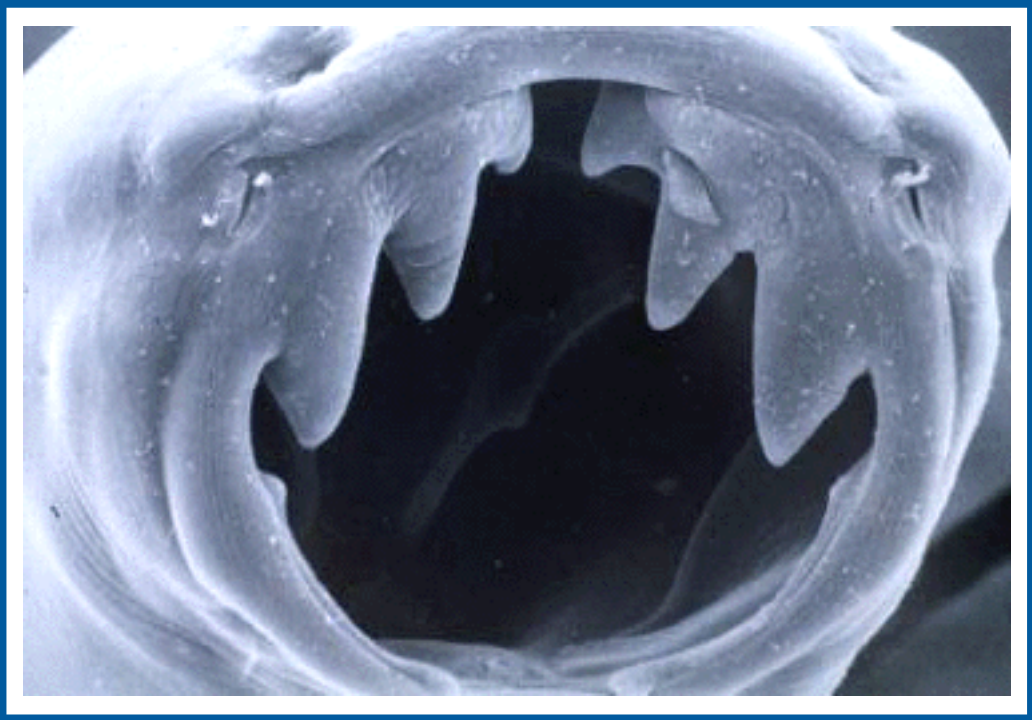

Shiba Kumar Rai
Shoji Uga
Nobumasa Kataoka
Takeo Matsumura

ATLAS
OF
MEDICAL PARASITOLOGY

Shiba Kumar Rai

Invited Foreign Rrsrarch Scientist
Department of Medical Zoology
Faculty of Medicine

Shoji Uga

Associate professor
Department of Medical Technology
Faculty of Health Science

Nobumasa Kataoka

Associate Professor
Department of Medical Technology
Faculty of Health Science

Takeo Matsumura

Professor
Department of Medical Zoology
Faculty of Medicine

Kobe University School of Medicine
Kobe,Japan

Front cover : Scanning electron microphotograph of hookworm(*Ancylostoma caninum*)mouth

Back cover : Scanning electron microphotograph of *Spirometra erinacei*

Printing press : Kyokuseisya Co.,Ltd.
1-2-7 Ninomiya-cho,Chuo-ku,Kobe651,Japan.

Dedicated

to

Scientists and Sufferers of Parasitic Diseases

Acknowledgments

It would have been impossible to prepare this atlas without the generous help of friends and colleagues who provided the photographs from their collections. We are grateful to them for the following photographs used in this atlas.

Dr. Eisaku Kimura, Department of Parasitology, Aichi Medical University, Aichi (Japan): **95, 96** ; Dr. Hisao Yoshikawa, Department of Biology, Nara Women's University, Nara (Japan): **20, 24**; Dr. Jeevan Shrestha, Department of Ophthalmology, Tribhuvan University Teaching Hospital, Kathmandu (Nepal): **85**; Mr. Mamoru Nakanishi, FALCO Biosystems, Kyoto (Japan): **8, 49**; Drs. Minoru Yamada and Tsunezo Shiota, Department of Parasitology, Kyoto Prefectural University of Medicine, Kyoto (Japan): **2, 5, 6, 9, Il, 12, 13, 21, 22, 23, 25, 26, 31, 32, 33, 52, 53, 56, 60, 61, 65, 94, 125, 126, 128, 131**; Dr. Rokuro Kano: 167; Dr. Toshimasa Nishiyama, Department of Parasitology, Nara Medical University, Nara (Japan): **3, 7** and Dr. Yuzo Takahashi, Department of Parasitology, Gifu University School of Medicine, Gifu (Japan): **113, 114.**

We take this opportunity to express our special gratitude to Professor Takashi Yamadori, Dean, Kobe University School of Medicine for writing foreword of this atlas. We are grateful to Japan Society for the Promotion of Science (JSPS) for inviting and supporting the stay of Shiba Kumar Rai (From Tribhuvan University Teaching Hospital, Kathmandu, Nepal in Japan (December 1, 1995 to March 31, 1996) as an Invited Foreign Research Scientist that provided us an opportunity to work together in various aspects of infectious diseases including the preparation of this atlas. Finally, we offer our sincere thanks to Kobe University School of Medicine, Kobe, Japan for financial support and to Kyokuseisya Co., Ltd., Kobe, Japan for the excellent and timely printing of this atlas.

S. K. Rai
S. Uga
N. Kataoka
T. Matsumura

Foreword

Parasitic infection is one of the major health problem in developing countries in tropical areas. However, because of increasing population and the international air travel, the parasites prevalent in tropics have now being frequently reported from industrialized countries as well.

In this context, it gives me a great pleasure to learn that the scientists working in the Faculty of Medicine of this Kobe University School of Medicine have prepared an ***Atlas of Medical Parasitology*** with an aim to provide a guide to the medical students and to newly qualified medical practitioners in diagnosing the parasitic diseases. I am confident that this atlas will be highly useful to its users.

I highly appreciate their efforts put forward in preparing this atlas.

7-5- I , Kusunoki-cho, Chuo-ku,

Kobe 650, Japan.

27th March, 1996.

Prof. Takashi Yamadori

Dean

Kobe University School of Medicine

Preface

Inspite of tremendous advancement made in the field of infectious diseases during past, many problems still remain. Of the various types of infectious diseases, parasitic infections yet constitute one of the major public health problem particularly in developing countries in tropical and sub-tropical areas. Many people in these areas are suffering from one or more than one parasitic infections and their sequelae. This has been attributed to low socio-economic standards, poor sanitary facilities, Iow education level and limited diagnostic facilities. Rapid and unplanned urbanization has also been found to be associated with the increase of parasitoses. In addition, increasing international travel and business have also contributed to the spread of parasitic diseases in countries once considered to have no or very low rate of parasitic infections. Therefore, the importance of parasitic diseases once said to be confined in developing countries is now emerging in developed countries as well.

This atlas has been prepared with an aim to provide a guide to the students of medical sciences and to newly qualified medical practitioners in diagnosing the parasitic diseases. In this atlas, a total of 167 photographs of more than 50 parasites of medical importance and some of the related clinical manifestations have been included. The parasites have been grouped as intestinal and urogenital, and blood and tissue parasites. Parasites like *Echinococcus, Toxocara, Anisakis, Gnathostoma,* and *Spirometra* are kept in the group of blood and tissue parasite as they are found in tissues in human. In addition, some of the ectoparasites have also been included. Brief recapitulatory introduction of parasite and respective caption for each of the photograph used have been given on the left. Scanning electron microscopic photographs of some of the parasites have also been included so as to provide an impression about the ultrafine surface structure of the parasites.

Inspite of our best efforts, we have been unable to include some other parasites of medical importance, and we apologize for the inconveniences caused by this reason.

S. K. Rai

S. Uga

N. Kataoka

T. Matsumura

Contents

Helminths

Others

Intestinal and Urogenital Protozoa

Entamoeba histolytica

(Phylum: Sarcomastigophora)

E. histolytica exists in two forms - trophozoite and cyst. The trophozoite and cyst measure 20-40 µm and 10-20 µm, respectively. Trophozoites are motile by means of short and blunt pseudopodia hence the outline is not clearly defmed. A clear ectoplasm and a dense granular endoplasm are well appreciated. The dense endoplasm contains nucleus, food vacuoles (sometimes host red blood cells). Trophozoite multiplies by means of random binary fission. Cysts, on the other hand, are round and resistant to external environment. It may contain one to four nuclei (uninucleate, binucleate and quadrinucleate) depending on the stage of maturation. The uninucleate and binucleate cysts contain glycogen mass and chromatin bars with blunt ends. Sometimes, a transitional stage, the so called pre-cyst can also be seen. It is worldwide in distribution, with high prevalence in tropical and sub-tropical areas. Infection in man takes place mainly by ingestion of mature (quadrinucleate) cyst through contaminated food or drinks. About 10% of world population are infected by this parasite with an incidence rate of less than 1% to as high as 90% in different part of the world. In man, it (trophozoite form) Iives in the colon and cysts are passed in the faeces. *E. histolytica* causes amoebic dysentery. Occasionally, it also causes abscess in liver, Iung and other parts of the body including the brain. Laboratory diagnosis of intestinal amoebiasis is usually done by the examination of stool samples using various techniques, most common being saline and iodine preparation. Trophozoites in faecal samples, however, are seen only in dysentric stool.

1. Trophozoite of *E. histolytica* in saline preparation (Phase contrast microscopy).

2. Trophozoite of *E. histolytica* (Merthiolate-Formalin stain).

3. Trophozoite of *E. histolytica* in sygmoidoscopied material with prominent ingested red blood cells (H & E stain).

4. Trophozoite of *E. histolytica* in liver tissue (H & E stain).

5. Uninucleate and binucleate cysts of *E. histolytica* in iodine preparation.

6. Quadrinucleate cyst of *E. histolytica* in iodine preparation.

7. Various types of amoebic lesions in colon. A. Typical amoebic ulcer; B. Ulcer folds; C. A Iarge ulcer with bleeding edge and D. Disc shaped ulcer surrounded by small healed ulcer scar.

Entamoeba coli

(Phylum: Sarcomastigophora)

E. coli differs from *E. histolytica* in various regards. It is bigger in size, the ectoplasm and endoplasm are not clearly differentiated, and food vacuoles contain only bacteria. The mature cyst contains eight nuclei. It is non-pathogenic, but occasionally found to be associated with diarrhoea.

8. Octonucleate cyst of *E. coli* in iodine preparation.

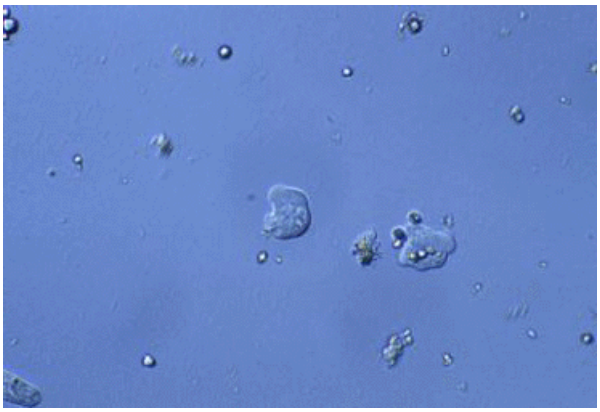

1

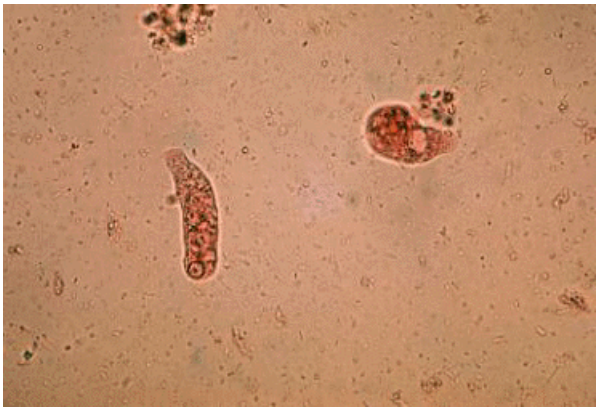

2

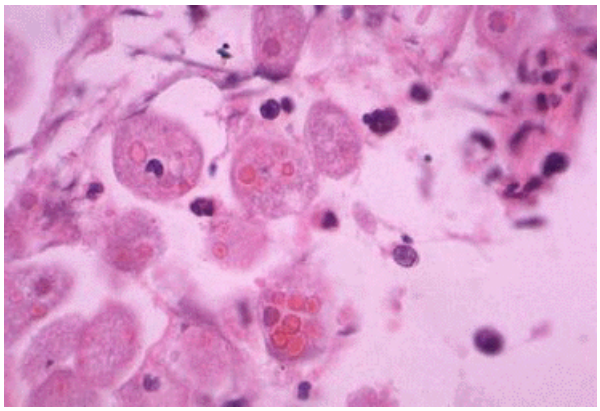

3

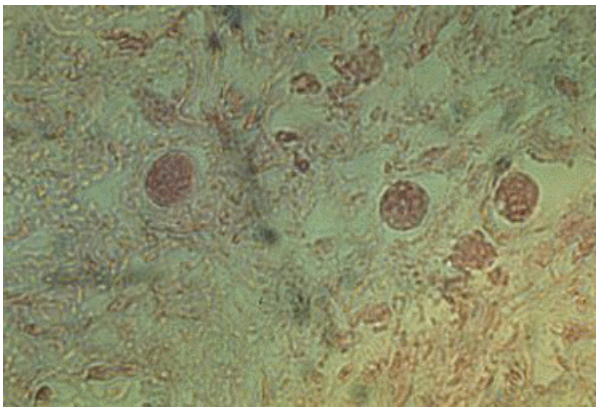

4

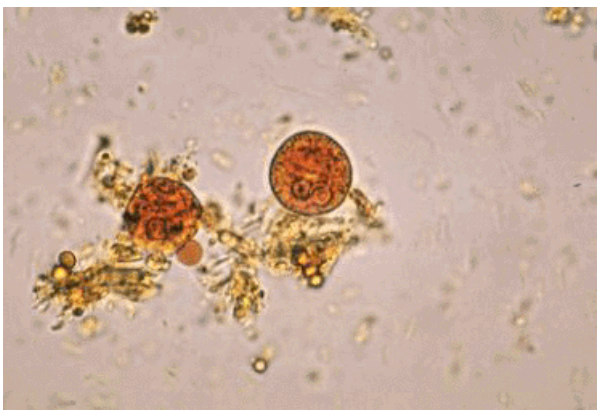

5

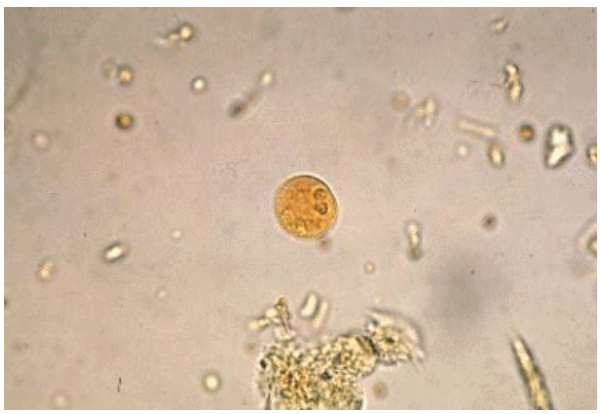

6

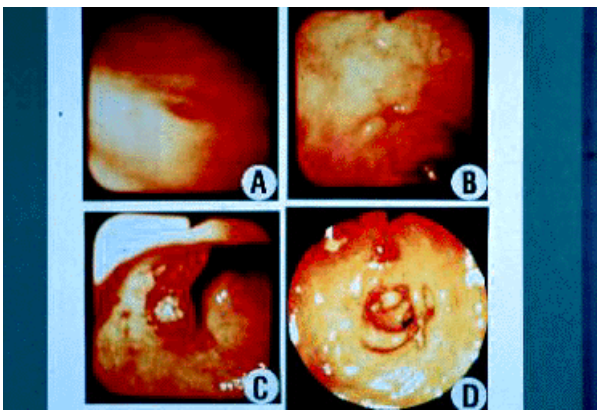

7

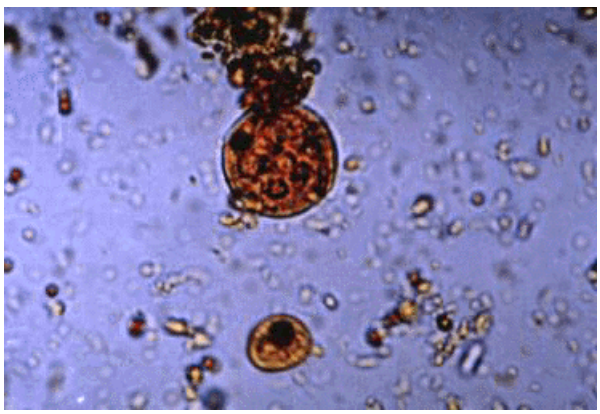

8

Naegleria species

(Phylum: Sarcomastigophora)

Naegleria is a free living amoeba of warm fresh-water and found throughout the world. *Naegleria* exists in flagellate form (with two flagella), in cystic form, and in amoebic form (with blunt pseudopodia). The flagellate form is elongate and exhibit speedy movement. The cysts are round and have thick cyst wall. The amoebic form is slug-shaped and shows a directional movement. The nucleus is distinct with centrally located nucleolus. The amoebic form is parasitic form of *Naegleria* and measures 8-12 µm in diameter. Infection in humans takes place by inhalation of free-living flagellate form usually while swimming (after nasal inoculation, penetrate the submucosal nerve plexus and the cibriform plate, and finally reach to frontal lobe of the brain). It causes primary meningo-encephalitis characterized by abrupt unset of fever, headache, nausea and vomiting leading to coma and death within a week. Diagnosis is made by detecting the parasite in wet cerebrospinal fluid (CSF) preparation. CSF also shows a neutrophilic pleocytosis, an elevated protein and a diminished glucose concentration.

9. *N.fowleri* (Amoebic form) in brain tissue section.

Giardia lamblia

(Phylum: Sarcomastigophora)

G. Iamblia exists in trophozoite and cyst forms. The trophozoites are badminton racket shaped (dorsoventrally convex) and are 12-15 µm in length. The axoneme extend from anterior end to posterior end forming the back bone of parasite. Two sucking (adhesive) disks are located at the flattened ventral surface. Two nuclei are present behind the each lobe of sucking disc. A pair of curved and transverse median body is present at the middle part of the body across the axoneme. It moves with the help of flagella (anterior flagella, posterior flagella, ventral flagella and caudal flagella) showing a falling leaf-like movement. The trophozoites live in duodenum. Cysts are oval and measures 8-12 x 7-10 µm in size. Cysts may contain two or four nuclei depending on the stage of maturity. It also contains rudimentary structure of axoneme and flagella. It is worldwide in distribution, but is most prevalent in tropical and sub-tropical areas. The infection rates in different part of the world vary from 2 to 67%. Infection in man takes place by ingestion of mature cysts through contaminated food or drinks. Water-borne epidemic of giardiasis occur frequently. It causes diarrhoea, stetorrhoea, and malnutrition. Giardiasis is common among children with poor hygiene. Diagnosis of giardiasis is usually made by detecting its cysts in saline and iodine preparations of faecal samples. Trophozoites are also detected by Entero test. Trophozoites in faeces are seen only during severe diarrhoea.

10. *G. Iamblia* (Trophozoite) (Giemsa stain).

11. Cyst of *G. Iamblia* in iodine preparation.

12. Cyst of *G. Iamblia* (India ink stain).

13. Cyst of *G. Iamblia* (Iron haematoxyllin stain).

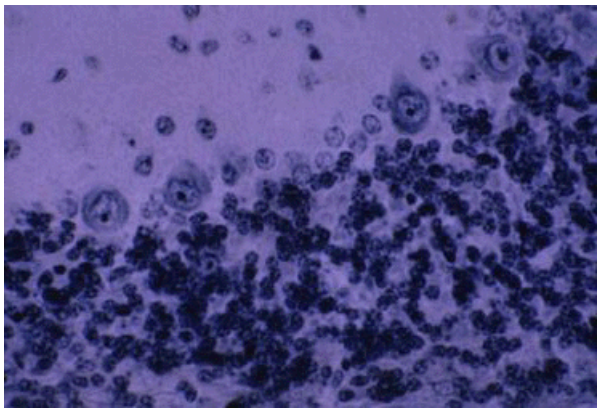

9

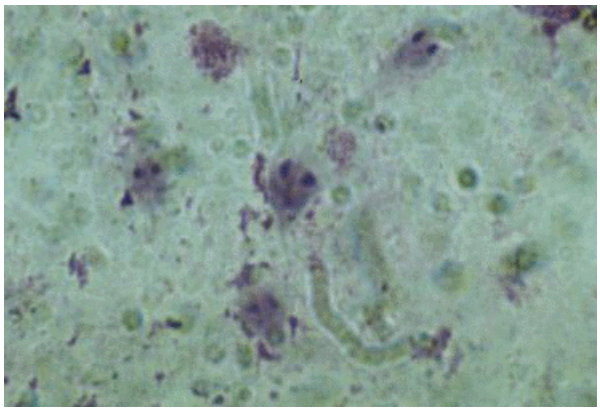

10

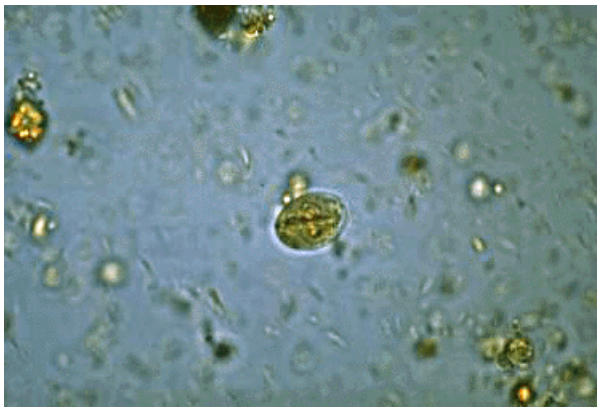

11

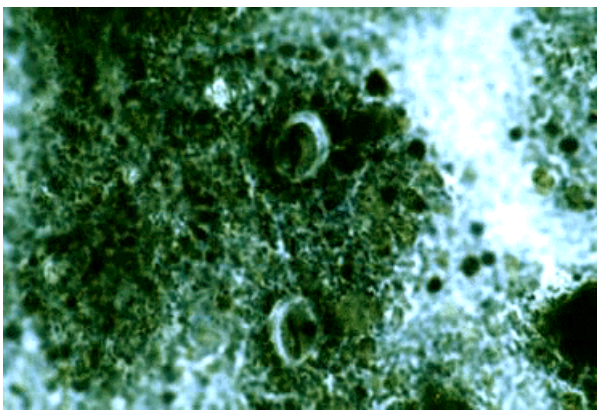

12

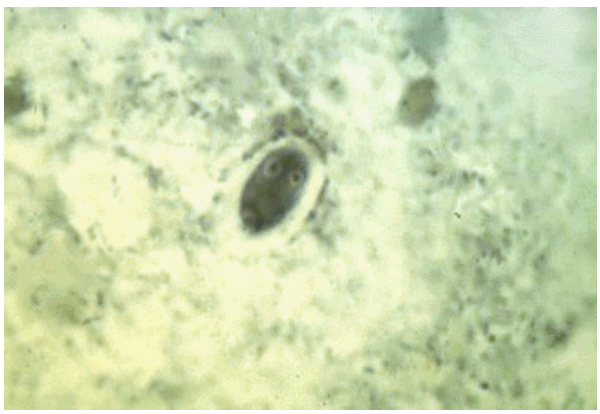

13

Cryptosporidium species

(Phylum: Apicomplexa)

Cryptosporidium spp. exist in the form of oocyst, sporozoite, meront, merozoite, gametocyte, and zygote during its complex life-cycle. The meront, merozoite, and gametocytes are formed in the upper small intestine. Some of the merozoites formed after two or three cycles of merogony undergo gametocytogony which finally give rise ' the formation of oocyst. Oocyst passed in faeces are round, highly refractile, and measure 4-6 µm in diameter. Oocysts are fully developed (contain four sporozoites _ without sporocyst) and are infective at the time of release. It is worldwide in distribution and has no host specificity (can infect man, cattle, horse, sheep, goat, rabbit, mice, chicken, and others including fishes and lizards). Infection in man takes place by ingestion of oocyst through contaminated food or drinks. It can cause both severe acute (as many as 70 motions in a day and as much as 17 Iitters of fluid loss in a day) and persistent diarrhoea particularly in children of less than three years and immunocompromised adults. It is one of the leading cause of death in AIDS patients. Laboratory diagnosis of cryptosporidiosis is done by faecal examination. Of the various techniques described, the sucrose centrifugal-floatation technique (observed under a phase contrast microscope) and modified AFB stain are commonly used for the detection of *Cryptosporidium* oocysts. Saline preparation is not useful in the diagnosis of cryptosporidiasis.

14. *Cryptosporidium* oocysts under light microscopy (Difficult to appreciate).

15. *Cryptosporidium* oocysts under phase contrast microscopy.

16. *Cryptosporidium* oocysts (Modified AFB stain).

17. *Cryptosporidium* oocysts of variable size (Phase contrast microscopy).

Isospora species

(Phylum: Apicomplexa)

Isospora exists in oocyst, sporozoite, meront, merozoite, gametocyte, and zygote forms during its complex life-cycle. The oocyst is eliptical, refractile and measure 30 x 12 µm in size. Inside the oocyst, there are two sporocysts each containing four sporozoites. It is mainly found in tropical and sub-tropical areas. Infection in man takes place by ingestion of oocyst. It causes diarrhoea, vomiting and sometimes even death. It is one of the important agent of traveller's diarrhoea. Laboratory diagnosis is made by detecting a characteristic refractile oocysts in faecal samples.

18. *Isospora* oocyst recovered from soil (Two sporocysts are clearly seen).

19. *Isospora* oocysts in faecal sample (Two sporocysts are clearly seen).

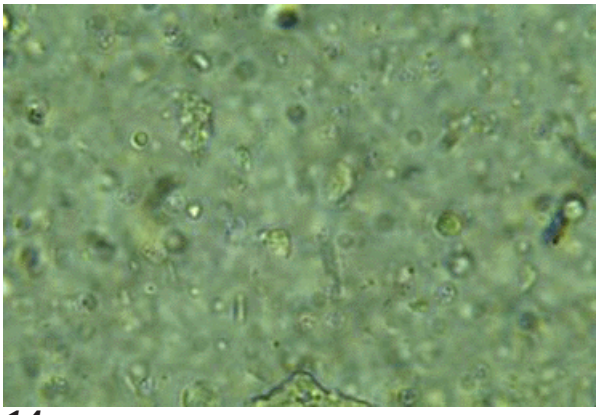

14

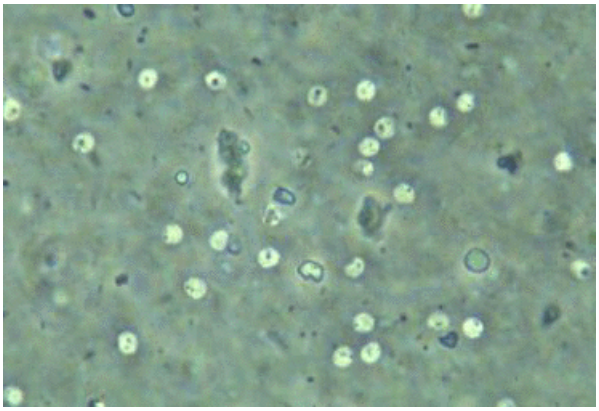

15

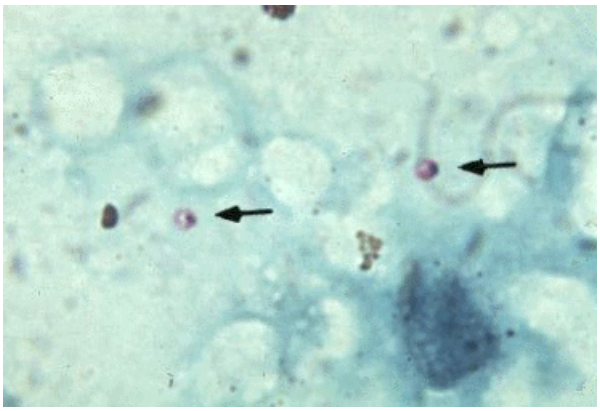

16

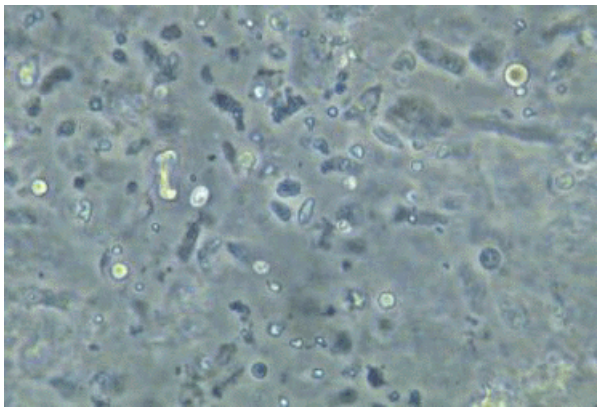

17

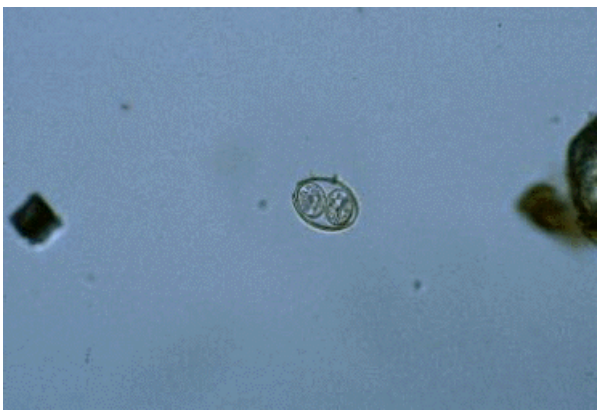

18

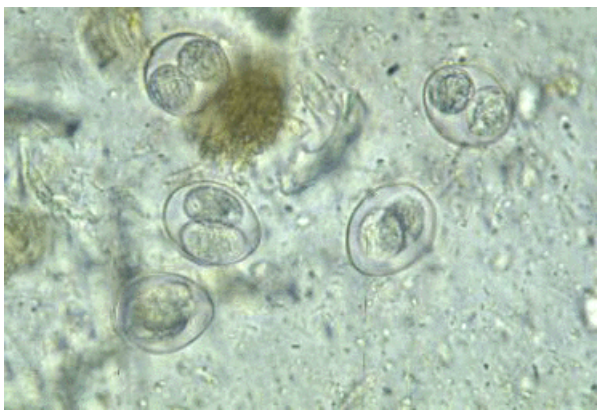

19

Blastocystis hominis

(Phylum: Apicomplexa)

B. hominis has recently been considered to be a protozoan parasite of man and other animals including birds and reptiles. It is round or oval in shape of different size varying from 5-20 µm in diameter. It contains large central vacuole. It is commonly found in intestinal content of healthy individuals. Recently, it is found to be associated with diarrhoea among immunocompromised individuals. Infection occurs through oral route. Diagnosis is made by detecting characteristic parasites in faecal samples.

20. *B. hominis* under phase contrast microscope.

21. *B. hominis* of variable size.

22. *B. hominis* in dividing phase (From culture).

23. *B. hominis* in India ink preparation.

24. *B. hominis* (Transmission electron microphotograph) (M: membrane, N: nucleus, G: Golgi body and CV central vacuole).

Balantidium coli

(Phylum: Ciliata)

B. coli is a ciliate protozoan parasite and exists in two forms - trophozoite and cyst. It is the largest protozoan parasite infecting man. It is spheroid in shape and measures 50-150 µm in length and 25-100 µm in width. The cytostome and cytopharynx lie at the pointed anterior end. The whole body is covered by cilia. There are two (micro and macro) nuclei. Macronucleus is kidney shaped. It moves with the help of cilia and is highly motile. Therefore, it is diffrcult to observe under the microscope and requires to be immobilized with the use of formalin. The cysts are round or oval in shape and measure 40-60 µm in size. Cyst contains both macro and micro nuclei. Infection in man takes place by ingestion of cysts through contaminated food or drinks. It is worldwide in distribution with higher incidence rate in the areas having pig farming. In man, it causes dysentery. Laboratory diagnosis is made by detecting characteristic cysts or trophozoites in the faecal smear.

25. *B. coli* trophozoite (Both micro and kidney shaped macronucleus are clearly seen).

26. *B. coli* cyst (Both micro and kidney shaped macronucleus are clearly seen).

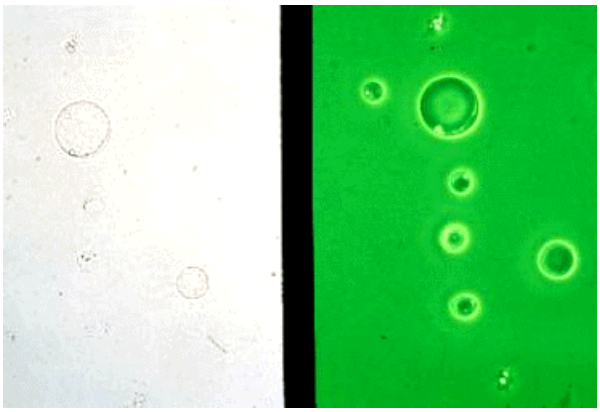

20

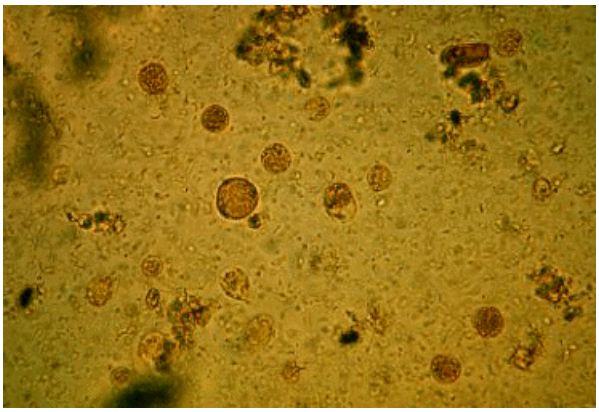

21

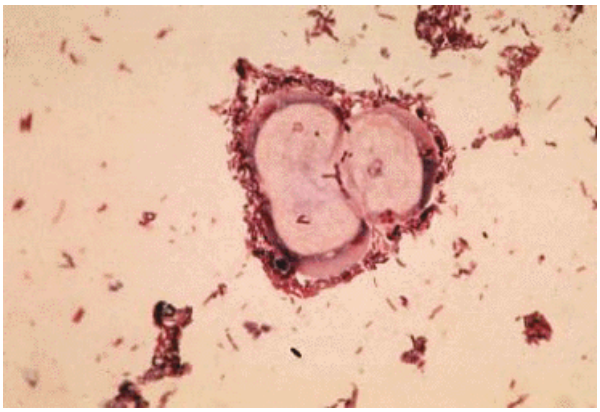

22

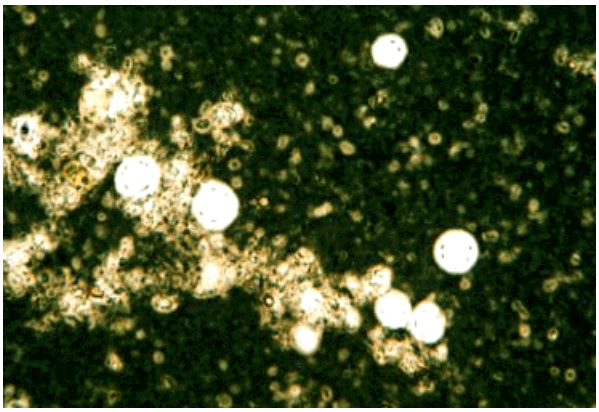

23

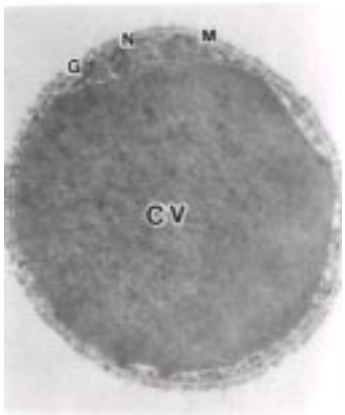

24

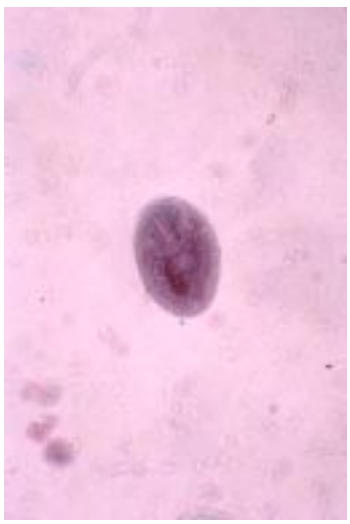

25



26

Trichomonas vaginalis

(Phylum: Sarcomastigophora)

T. vaginalis is a urogenital flagellate protozoan parasite that exists only in trophozoite form. It is pear-shaped and measures 10-30 μm in length and 5-10 μm in width. A tuft of five flagella is originated from the anterior end, one out of which forms an undulating membrane ending posterior to the middle of the body. A costa is present beneath and runs parallel to the undulating membrane. As the flagella are originated only from anterior end, it shows a wriggling movement in wet preparation. The nucleus with scattered chromatin granules is located at the anterior end. A tube-like axostyle extends posteriorly and protrudes from the body forming a caudal tip. There are granules along the costa and the axostyle. This parasite lives in the vagina and urethra of woman (thus the name vaginalis), and in the urethra, prostate and seminal vesicle of man. It is distributed in all over the world with variable incidence rate. Infection is transmitted by sexual intercourse. Transmission from infected male to female is hundred percent. In female, it causes vulvitis and vaginitis (with itching and leukorrhoea), cervicitis, and even salpingitis. In male, it causes urethritis, prostitis, and epidymitis. Diagnosis of trichomoniasis is usually done by detecting the parasite in urinary deposit, vaginal discharge, high vaginal swab in case of female, and in urine and semen in case of male. In the freshly prepared saline preparation or in urinary deposit a typical movement of *Trichomonas* is seen.

27. *T .vaginalis* in wet preparation (Phase contrast microscopy).

28. *T .vaginalis* (Scanning electron microphotograph).

29. *T .vaginalis* (Scanning electron microphotograph).

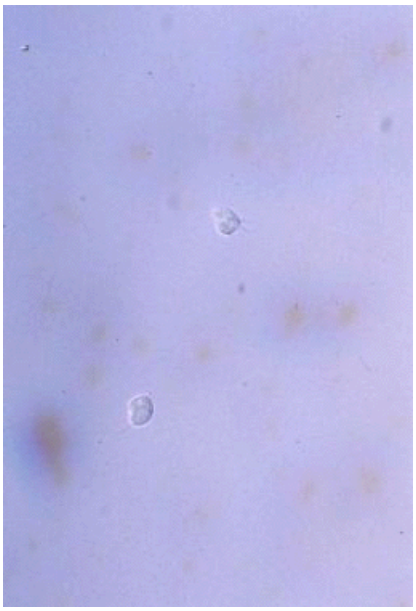

27

28

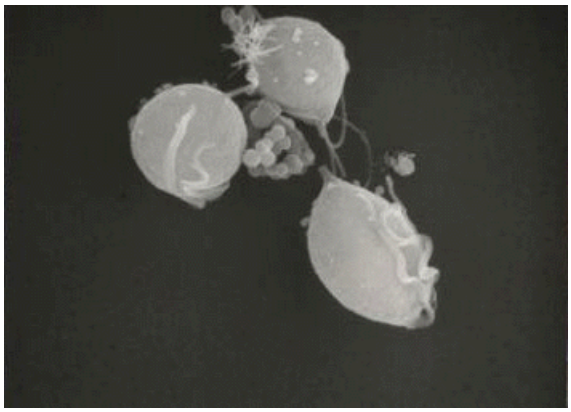

29

Intestinal Helminths

Ascaris lumbricoides

(Phylum: Nemathelminth)

A. Iumbricoides is one of the most common helminthic parasite of man. It exists in three forms - adult worm, egg (ova) and larva during its life-cycle. The adult worms are creamy-white in colour. Females are bigger (20-40 cm in length and 3-6 mm at its greatest width) than males (15-30 cm in length and 2-4 mm at its greatest width). At the anterior end, there are three prominent lips with dentigerous ridge. Posterior end of male is curved ventrad. The tail is bluntly pointed. The spicules in male genital organ are simple and measure 2-3 µm in length. In female, vulva is present at about one third of the body length from the anterior end. One female Ascaris can lay 200 to 200,000 eggs (ova) per day. Both fertilized and unfertilized female worms can lay the eggs, and eggs are golden brown in colour (bile stained). The fertilized ova are round or oval with thick and lumpy outer albuminous layer and measure 50-70 µm in diameter. The unfertilized ova are longer and narrower measuring about 80-90 x 40-50 µm in size. It is worldwide in distribution. Approximately 20% of world population are infected by this parasite with a very high prevalence (90%) in certain tropical and sub-tropical areas. Infection in man takes place by ingestion of embryonated eggs through contaminated food or drinks (unfertilized eggs are non-infectious). The larvae hatched in the intestine penetrate the intestinal wall and travel to the liver, heart, Iung, trachea, larynx, and finally reach again in small intestine and develop into adult worm. The adult worms live in the middle part of small intestine. Adult worms cause diarrhoea, fever, malnutrition, appendicitis, jaundice and intestinal obstruction. The migrating larvae in the lung cause ascaris pneumonia (Loeffler's syndrome). Diagnosis of ascariasis is made by detecting its eggs in faeces and sometimes adult worms also. Occasionally, Iarvae also can be detected in sputum sample.

30. *A. Iumbricoides* male and female adult worms.

31. *A. Iumbricoides* egg (Fertilized).

32. *A. Iumbricoides* egg (Fertilized decorticated egg).

33. *A. Iumbricoides* egg (Unfertilized).

34. *A. Iumbricoides* egg recovered from soil (Fertilized).

35. *A. Iumbricoides* eggs recovered from soil (Embryonated).

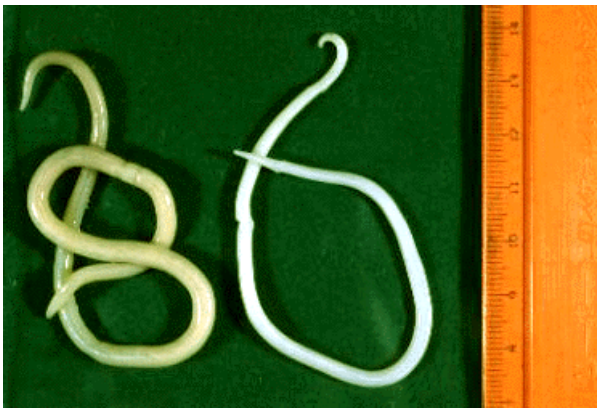

30

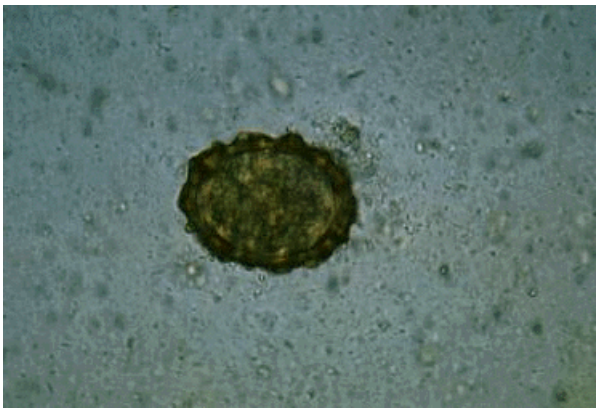

31

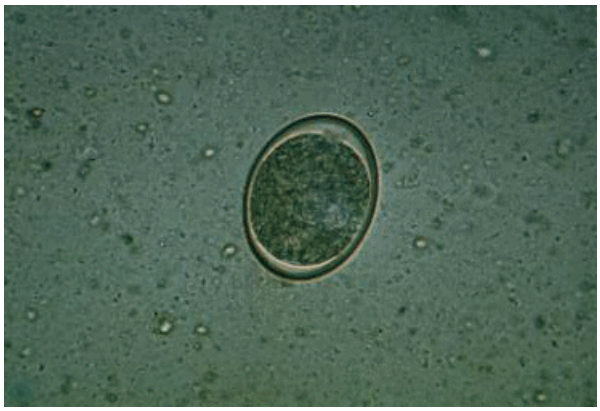

32

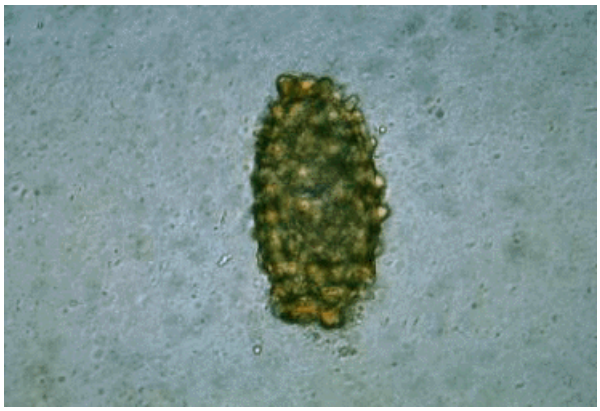

33

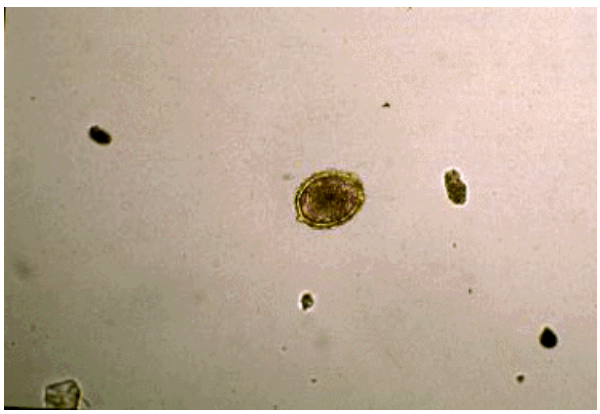

34

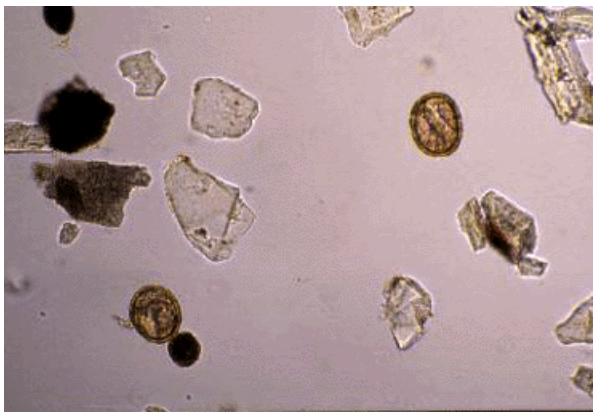

35

Trichuris trichiura

(Phylum: Nemathelminth)

T trichiura is one of the most common intestinal parasite of man. Adult worm measures 30-50 mm in length, male being relatively smaller with coiled posterior end. The anterior part of the body is thin and long (two third of the body length) whereas the posterior part is thick and stout, thus appears as a whip. Mouth is simply an opening and does not contain any lips. Anus is located near the tip of tail. Male has single spicule surrounded by a spiny sheath. One fertilized female worm lays 1,000-7,000 eggs per day. Eggs are barrel shaped, golden-brown in color and measure 50 x 25 µm in size. Embryonation takes place in environment. Approximately 10% of world population are infected by this parasite. Infection takes place by ingestion of embryonated eggs through contaminated food or drinks. Larva hatches in the small intestine and develop into adult worm. Adult worms live several years in the caecum and ascending colon by burrowing the mucosa. Most infections are asymptomatic, but heavy infections cause abdominal discomfort, anaemia, bloody diarrhoea, rectum prolapse and appendicitis. Diagnosis of trichuriasis is made by detecting characteristic eggs in the faecal sample.

36. *T .trichiura* egg.

37. Appendix section showing *T.trichiura* oesophagus with charactristic sticocytes

(H & E stain).

Trichuris vulpis

(Phylum: Nemathelminth)

T. vulpis is found in caecum of dogs and foxes. *T vulpis* is morphologically similar to T trichiura. However, the egg of *T.vulpis* is relatively bigger than that of *T. trichiura.*

38. *T.vulpis* adult worm.

39. *T.vulpis* adult worm in dog caecum.

40. *T.vulpis* egg.

41. *T.vulpis* egg (Embryonated).

36

37

38

39

40

41

Hookworm

(Phylum: Nemathelminth)

Hookworm consists of five species of *Ancylostoma (A. duodenale. A. caninum, A. braziliense, A. ceylanicum. and A. malaynum)* and one species of *Necator (N. americanus)*. Of these, *A. duodenale* and *N. americanus* are human intestinal hookworms and others being the animal hookworms. The anterior end is dorsally curved forming a hook-like appearance, hence the parasite is called hookworm. The adult worms are brown at the time of passing. The buccal capsule is big and is armed with cutting plate, teeth or dorsal cone (varies with genus and species). Lips are not present. Males have a conspicuous copulatory bursa, consisting of two broad lateral lobes and a smaller dorsal lobe supported by a fleshy ray. Spicules are simple and needle-like in appearance. A gubernaculum is present. Females have simple conical tail. The vulva is located at about three-fifth of the body length from the anterior end. One fertilized female worm produce thousands of eggs per day for as long as nine years. Female worms are bigger than males. Adult *A. duodenale* male and female worms measure 8-11 mm and 11-13 mm in length, respectively. *A. duodenale* are relatively bigger and more pathogenic than *N. americanus*. The eggs are colourless, oval in shape, measure 70 x 40 µm in size and contain four blastomeres in it. A rhabditiform larva (250-300 µm) is hatched from the egg which further grow into a non-feeding filariform larva (500-700 µm). Approximately 20% of world population are infected by this parasite. Infection takes place by skin penetration by the filariform larvae. Some species can also infect through oral route. The larvae then migrate to the heart, Iung, trachea, Iarynx and finally reach to the upper small intestine where they grow into adult worm. Adult worms attach to the mucosa by means of buccal capsule and feed on blood and tissue. Blood loss caused by the adult worm lead to anaemia and its sequelae. It also causes hunger pain. Migrating larvae, in the lung, cause pneumonitis. The filariform larvae cause pruritis (ground itch) at the site of skin penetration. Diagnosis of hookworm infection is made by detecting the characteristic eggs in the faecal sample. Other non human species of *Ancylostoma*, when infecting in human, cause cutaneuos larva migrans which is characterized by creeping eruption of skin.

42. Hookworm egg with distinct blastomeres.

43. Hookworm egg with many blastomeres (Slightly old faecal sample).

44. Adult hookworms (Brown coloured due to blood feeding) on cut open surface of upper small intestine.

45. Adult hookworm.

46. Mouth part of *Ancylostoma caninum* (Under light microscope).

47. Mouth part of *Ancylostoma caninum* (Scanning electron microphotograph).

48. Mating of hookworms (Scanning electron microphotograph).

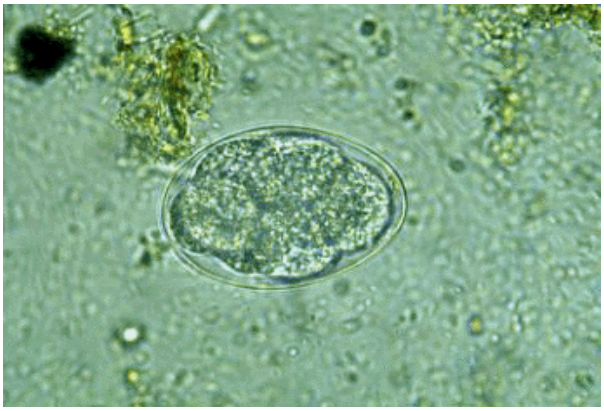

42

43

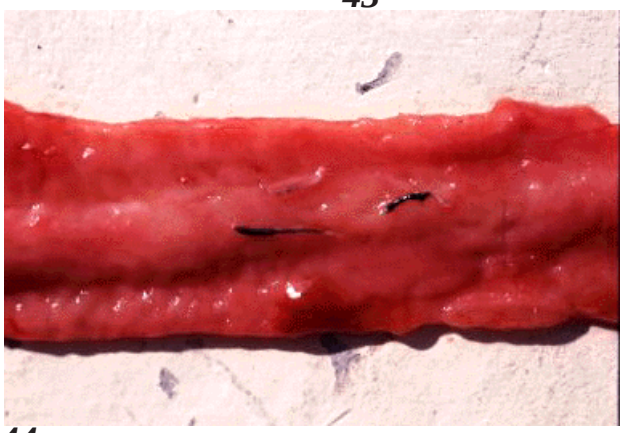

44

45

46

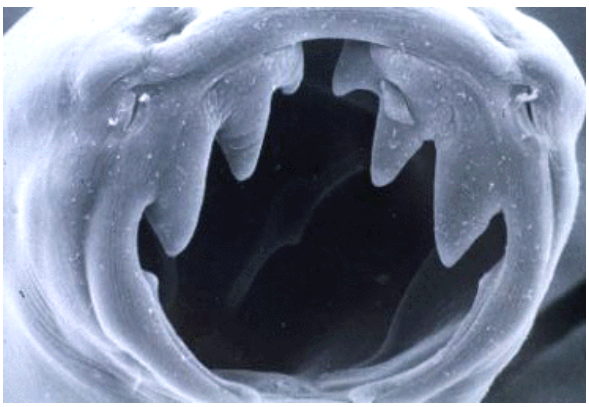

47

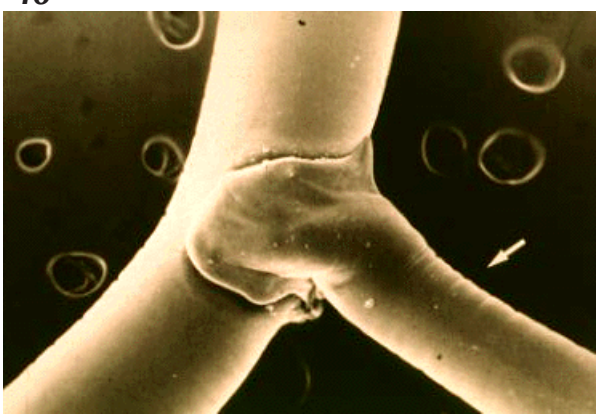

48

Strongyloides stercoralis

(Phylum: Nemathelminth)

The parthenogenetic *S. stercoralis* female worm measure 1.5-2.5 mm in length (controversy exist about the parasitic male). Free-living male adult worm is 1.0 mm long and has two simple spicules at its pointed and ventrally curved tail. The females are stout and the vulva is located at the middle of the body. They have small buccal capsule and a long cylindrical oesophagus without posterior bulb. The parasitic female produce thin-shelled and partially embryonated eggs (50 x 30 µm) in the intestinal mucosa. A Iarva measuring 250-300 µm long hatched from the egg comes to the intestinal lumen and then passed in the faeces. In the environment, the larva either develops into a free living adult worm or into an infective filariform larva of 500-700 µm in length. Infection in man takes place by skin penetration by filariform larvae. However, autoinfection (sometimes the larvae hatched inside the intestine develop into the filariform larvae by the time they reach to anus and then enter into the body by penetrating the skin and mucosa around anus) also does occur. It is worldwide in distribution with a high prevalence in tropical and sub-tropical areas. It causes allergic pruritis, Iarva migrans, pneumonitis, and diarrhoea. Hyperinfection may lead to disseminated strongyloidiasis particularly among the AIDS patients. Diagnosis can be made by detecting a rhabditiform larvae in freshly passed faecal sample. Confirmatory diagnosis is made by examining the filariform larva after culture.

49. *S. stercoralis* rhabditiform larva.

50. *S. stercoralis* filarifom larva.

51. Tail portion of rhabditiform larva (Right) and filariform larva (Left).

Enterobius vermicularis

(Phylum: Nemathelminth)

E. vermicularis has separate sexes. Female is bigger (8-12 mm in length) than male (2-5 mm in length). The posterior end of male is strongly curved and bears a single, simple spicule (70 µm in length) and a conspicuous caudal alae supported by papilae. The posterior end of female is extended into a long slender point (pin-like appearance) hence the name pinworm. The adult worms live in the caecal area where from the gravid female worm migrate at night to the perianal area to lay their eggs. Eggs are colorless, plano-convex and measure 50-60 x 20-30 µm in size. Infection in man takes place by ingestion of eggs. Sometimes retro-autoinfections (larvae hatched at perianal area enter into the intestine and develop into the adult worm) also occur. This parasite infection is more common in crowdy and poor hygienic areas. Migration of gravid female worm to anal area causes itching and sleeping disturbance. Occasionally, it also causes appendicitis, ulcerative colitis, vaginitis and salpingitis in females. Diagnosis is made by detecting a characterisitic eggs in cellophane tape preparation prepared by touching perianal region early in the morning.

52. *E. vermicularis* egg.

53. *E. vermicularis* adult worm.

49

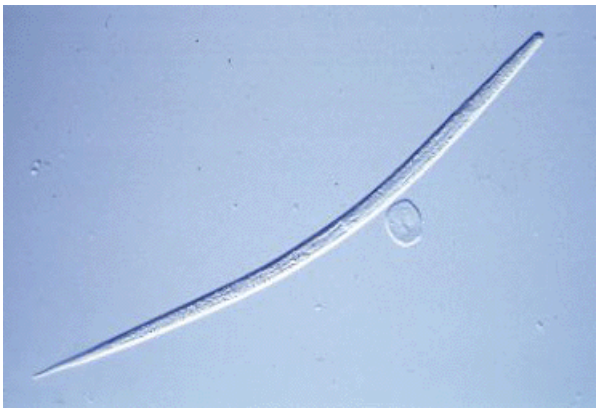

50

51

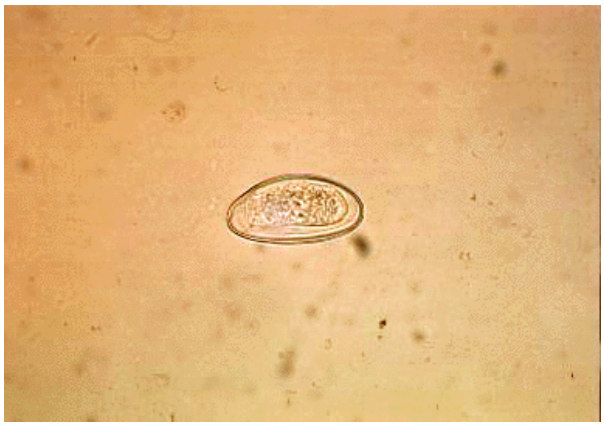

52

53

Taenia species

(Phylum: Platyhelminth)

T.solium (pork tapeworm) and *T. saginata* (beef tapeworm) are the two species of *Taenia* that infect man. These parasites are hermaphrodite and are very long enough to measure in metres (*T. solium* measure 3-5 meter while that of *T. saginata* measures 5-10 meter). The body is divided into head, neck and a long segmented body (strobilla). The head size is about 1 mm in diameter. Head of both species bears four suckers. The head of *T. solium* has a rostellum armed with hooklets. In contrast, the head of T. saginata does not have the armed rostellum instead a depression. Each segment contains independent male and female sex organs. The terminal mature segments measuring 15-25 x 5-7 mm keep on detaching from the body and are passed in the faeces. There are more than 15 Iateral uteral branches in each segment of *T. saginata* whereas the T. solium segment contains less than 15 Iateral uteral branches. The eggs are golden brown in colour, measure 30-40 µm in diameter and are indistinguishable morphologically. The onchosphere bears three pairs of hooklets. Both of these parasites are world-wide in distribution. Infection of man takes place by ingestion of larva *(Cysticercus cellulosae or Cysticercus bovis)* present in raw or undercooked pork *(T. solium)* or beef and meat of other herbivorous animals *(T. saginata)* (intermediate hosts). Both of these parasites live in the small intestine of infected man and cause vague intestinal disorder and malnutrition. Diagnosis of taeniasis is made by detecting characteristic eggs, segments and heads in the faecal sample.

Ingestion of T. solium eggs by man result into a disease called cysticercosis (neuro, ocular, cutaneous or disseminated). Cysticercosis also results from autoinfection (sometimes the mature terminal segments are thrown into the stomach where the eggs are released). Diagnosis of cysticercosis is made by detecting cysticerci in histological examination of tissue, by personal history of the residence in the endemic areas, eating history of pork, or by serological means.

54. *Taenia* egg.

55. Gravid segment of *T. solium* (Uteral branches stained by India ink).

56. Gravid segment of *T. saginata* (Uteral barnches stained by India ink).

57. Gravid segment of *T. saginata* (Stained by Carmine stain).

58. *T. saginata* adult worm.

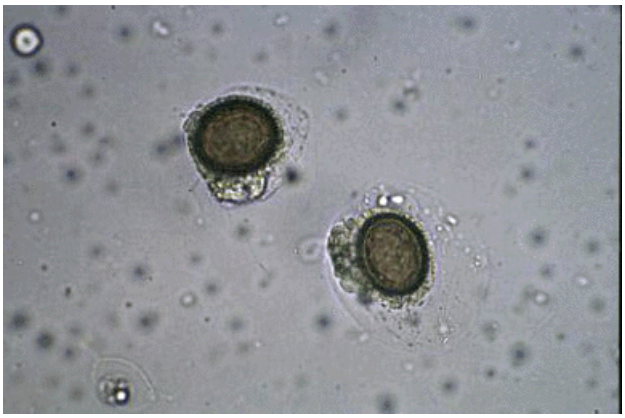

54

55

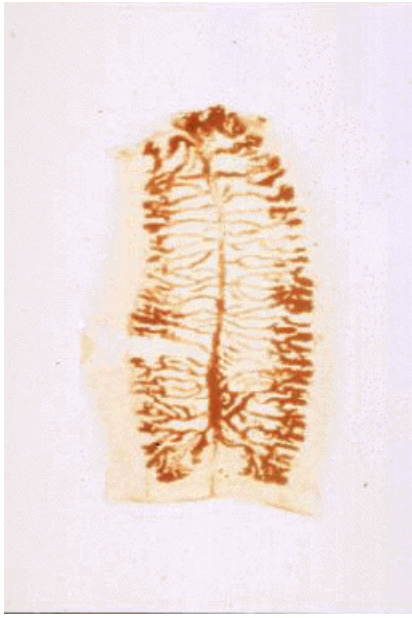

56

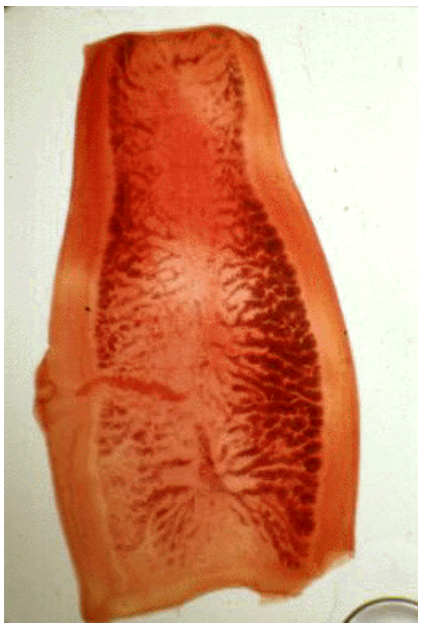

57

58

Hymenolepis nana

(Phylum: Platyhelminth)

H. nana is the smallest platyhelminth (not more than 40 mm in length) to infect man and may not require an intermediate host to complete its life-cycle. The head bears four suckers and a rectangular rostellum armed with a single row of hooklets. There are about 200 segments and each segment is wider than long. As in the case of other tapeworms, each segment bears both male and female sex organs. The eggs are oval or round, colourless or clay coloured, measure 40-50 μm in diameter, and are passed in faeces. The onchosphere bears three pairs of hooklets and has polar thikening at either end. There are polar filaments between membranes. It is worldwide in distribution. Infection in man takes place by ingestion of eggs through contaminated foods or drinks. Autoinfection (the onchosphere hatched while the eggs being inside the intestine penetrate the villi and develop into cysticercoid that later come out in the lumen and grow into adult worm as in the case of primary infection) also occurs. Therefore, *H. nana* is the only tapeworm that can complete its life-cycle without coming out from the definitive host. It causes bowel irritation and associated manifestations. Diagnosis is made by detecting the characterisitic eggs in the faecal sample.

59. *H. nana* egg.

60. *H. nana* adult worm.

61. *H. nana* in small intestine (H & E stain).

Hymenolepis diminuta

(Phylum: Platyhelminth)

H. diminuta is primarily a tapeworm of rat and mouse but often infects humans. It is bigger than *H. nana* (about 80 cm in length) and the rostellum is not armed with hooklets. The eggs are relatively bigger (60-70 μm) than that of H. nana and does not have polar filaments between the membranes. Many species of arthropods serve as an intermediate host, most common being stored-grain beetles. Rests are similar to *H. nana.*

62. *Hymenolepis nana* By Itoh.

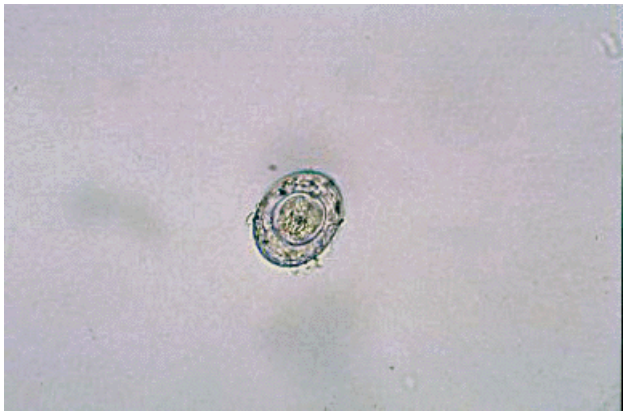

59

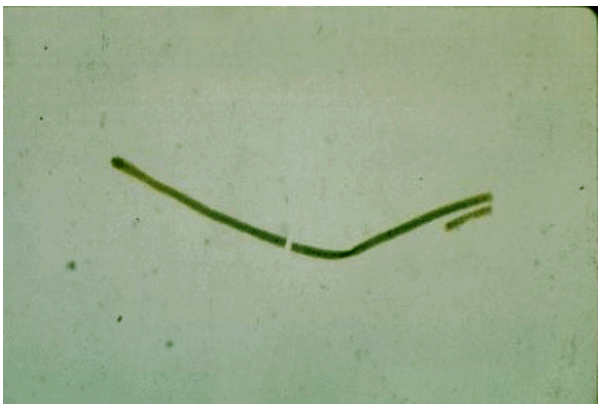

60

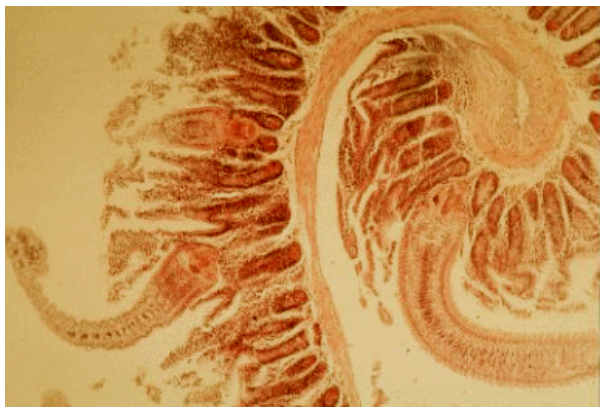

61

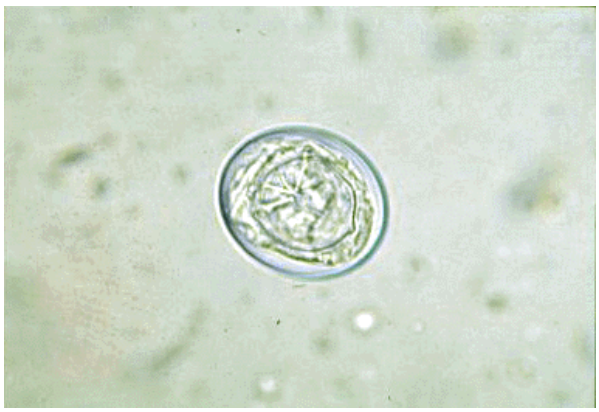

62

Diphylobothrium latum

(Phylum: Platyhelminth)

D. Iatum measures about 10 meters in length. The body is divided into head, neck and segments. Unlike the head of other tapeworm, the head of *D. Iatum* is finger shaped and has two longitudinal sucking grooves (dorsal and ventral) called bothria instead of the suckers. The segments are usually wider than long. The terminal segments are usually released in a long chain. Eggs are oval in shape and measure 60 x 40 µm in size. It has an operculum at one end and a knob at the other end. This parasite completes its life-cycle in three different hosts. The coracidium released from eggs are infective to the cyclops in which it develops into a larva. Subsequently, the larvae containing cyclops is eaten up by the fish into which it undergoes further development and becomes infective to the defmitive host. This parasite has no strict host specificity and infects various fish eating animals including man. In certain pockets of area, nearly 100% peoples are infected by this parasite. Infection in man takes place by ingestion of infective Iarvae present in raw and/or undercooked fish. It causes vague abdominal discomfort and megaloblastic anaemia. Diagnosis is made by detecting the characteristic eggs in the faecal sample, or by observing the excreted segments morphologically.

63. *D. Iatum* eggs.

64. Body of *D. Iatum* adult worm.

65. *D. Iatum* adult worm.

Dipylidium caninum

(Phylum: Platyhelminth)

D. caninum is common tapeworm of dogs and cats. It measures about 20-40 cm in length and each segment has characteristic two vaginal openings (double-pored). The scolex is rectangular with pointed rostellum and several rows of rosethron-shaped hooklets. The four weak suckers are circled with double rows of spines. Mature segments are longer than wide and appear as cucumber seed. The terminal segment when passed in the faeces is very active. Mature segments contain egg capsules with 5-20 eggs within them. The eggs are round and the onchosphere contains hooklets. Free eggs, however, are rarely found. Fleas are the usual intermediate host of this parasite. It is distributed world-wide. Human infection, mainly in children, takes place by ingestion of dog fleas while hugging or kissing the pets. It causes abdominal disturbances in infected indivisuals. Diagnosis is made by detecting characteristic segments and rarely egg packets in the faeces.

66. *D. caninum* egg packet.

67. Body of *D. caninum* adult worm.

68. Scolex of *D. caninum* (Scanning electron microphotograph).

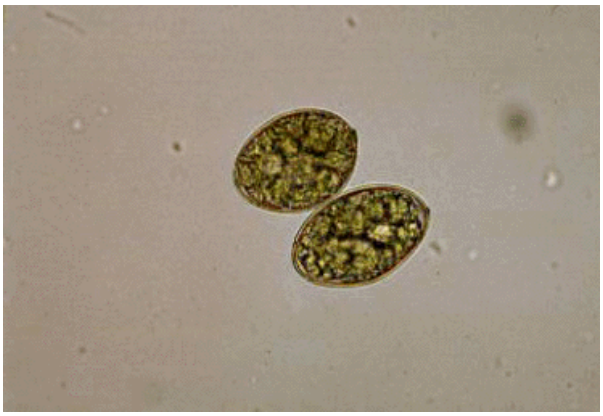

63

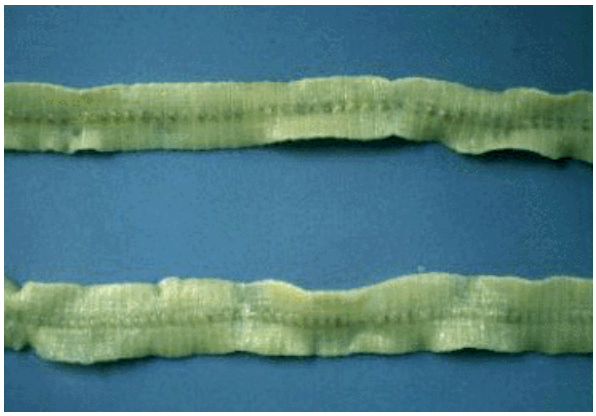

64

65

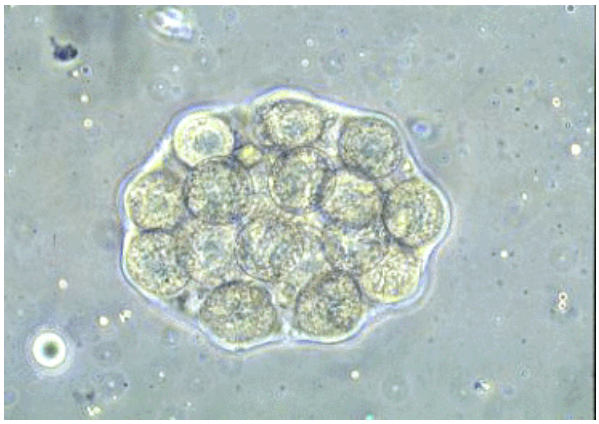

66

67

68

Blood and Tissue Protozoa

Plasmodium species

(Phylum: Apicomplexa)

Four species of *Plasmodium* can infect man and cause the number one killer parasitic disease - the malaria. The species infecting man are: *P. falciparum, P vivax, P. ovale,* and *P. malariae*. These parasites complete its life-cycle in two hosts man (intermediate host) and female anopheline mosquitoes (definitive host). The sporozoites (10-15 µm long with I µm in diameter) injected by female anopheline mosquito during its blood feeding undergo pre-erythrocytic schizogony (liver schizogony) inside the liver cells. In case of *P. vivax* and *P. ovale*, some of the sporozoite reached to liver cell remains in hypnozoite form that are responsible for relapse. The merozoites (2.5 µm long with 1.5 µm in diameter) released from the liver schizont then enter into the erythrocytic schizogony (blood schizogony) which is most important from the diagnostic point of view. In the blood smear stained by Romanowsky stain, preferably the Giemsa stain, the parasite appears in "ring" form, trophozoite, early schizont, and mature schizont (all inside the infected red blood cells) and an extracellular male. and female gametocytes. All of these forms differ from one. species to another in their morphology. Generally, schizont of *P. falciparum* is not seen in peripheral blood smear, and its gametocyte is of typical "banana" shaped. *P. vivax* and *P. ovale* generally infect young RBC thus are bigger, *P. malariae* infects mature RBC while that of *P. falciparum* infects both immature and mature RBC in the circulation. The male and female gametocytes ' ingested by female anopheline mosquitoes undergo oogony that finally gives rise to the infective sporozoites. *Plasmodium* infection of man occurs through mosquito bite, but occasionally it may also be occurred through blood transfusion and through transplacental transmission (congenital malaria). Infection is more prevalent in tropical and sub-tropical developing countries while in industrial countries it is limited only in and around the airport and ship-yard. Generally malaria is characterized by classical tertian (*P. falciparum, P. vivax and P. ovale*) and quartan (*P. malariae*) types of fever. *P. falciparum*, however, also cause the deadly complicated malaria. In many parts of the world, malaria parasites have developed the drug resistancy as well. Diagnosis of malaria is usually made by detecting the parasites in the blood smear. In addition, serology, polymerase chain reaction (PCR) and other techniques can also be used.

69. *P. falciparum* ring stage.

70. *P. falciparum* gametocytes (Banana shaped).

71. *P. vivax* ring stage.

72. *P. vivax* trophozoite stage.

73. *P. ovale* ring stage.

74. *P. ovale* early schizont.

75. *P. malariae* ring stage.

76. *P. malariae* trophozoite stage.

77. Acridine orange staining of malaria parasites (Positive; almost all RBC contain acridine orange stained malaria parasites).

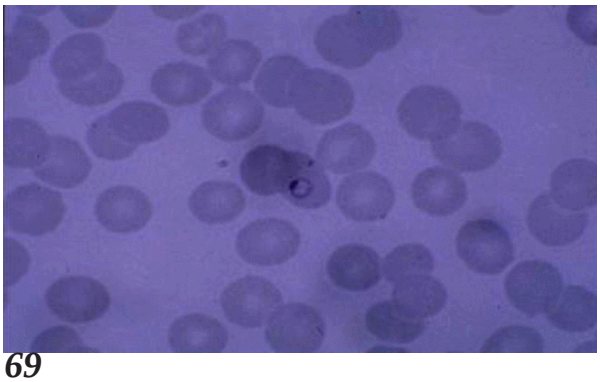
69

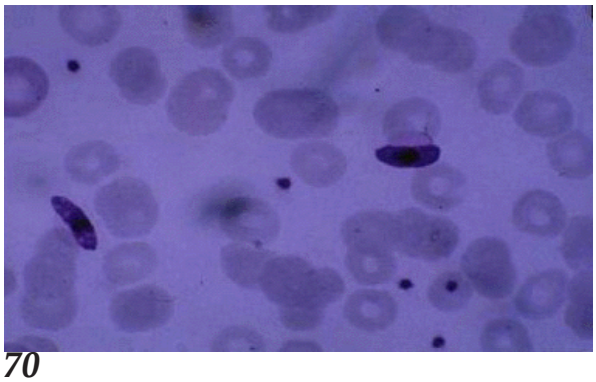
70

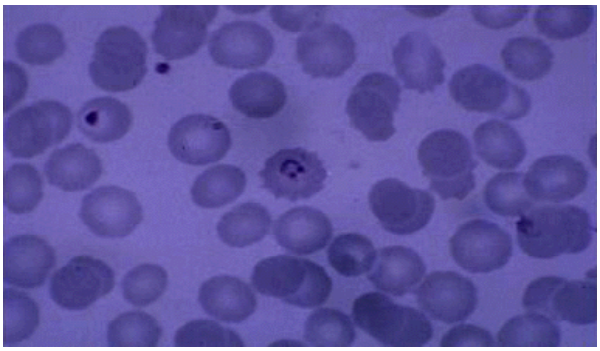
71

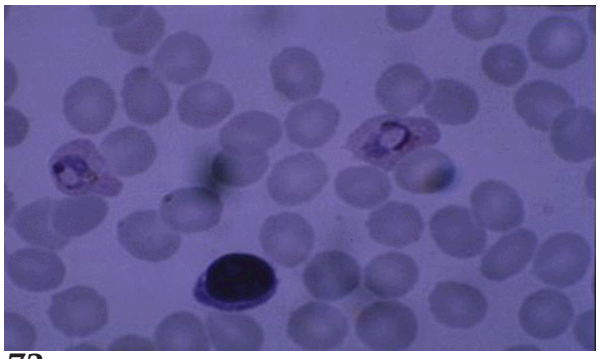
72

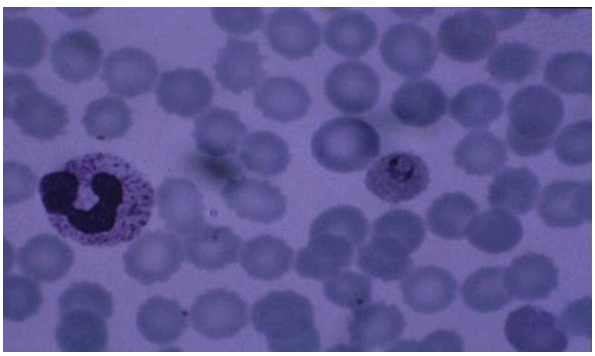
73

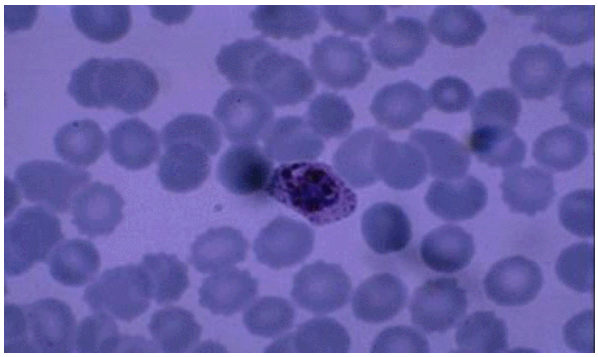
74

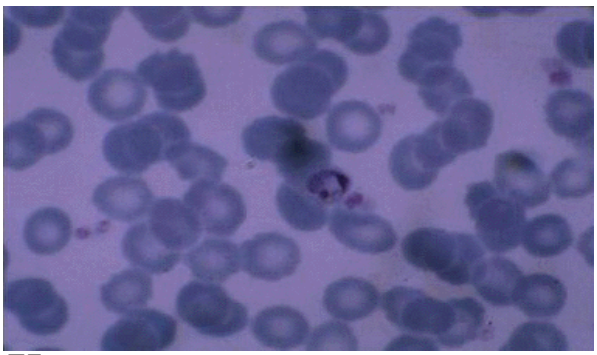
75

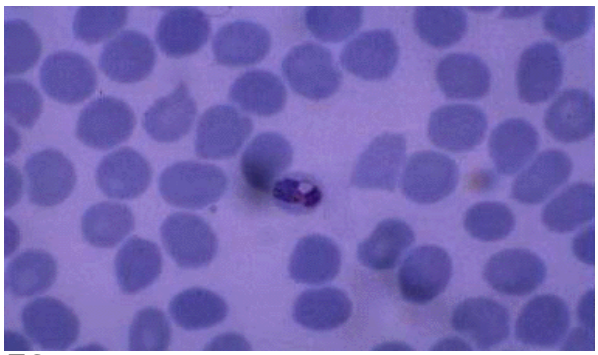
76

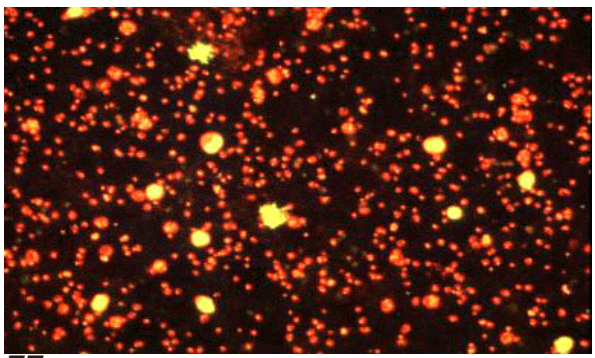
77

Toxoplasma gondii

(Phylum: Apicomplexa)

T.gondii is a cosmopolitan parasite infecting a wide range of animals including birds and man. Felines (cat and others) act as definitive host for this parasite while others act as intermediate host. The sporulated oocyst (10-13 x 9-11 μm) passed in the faeces of definitive host are infective to all intermediate hosts. Oocyst contains eight sporozoites enclosed within two sporocysts. Upon ingestion by intermediate hosts, the sporozoites released from oocyst enter into all types of nucleated cells particularly in phagocytic cells and initiate multiplication. In the intermediate host, it is found in two forms: tachyzoite (the rapidly proliferating form) and bradyzoite (the slowly proliferating form). They are crecent shaped (6 x 3 μm) and undergo multiplication inside the phagocytic cells, but can infect all nucleated cells. On the other hand, the bradyzoites are enclosed within a cyst and are found in tissues including the brain. One cyst may contain thousands of bradyzoite. These tachyzoites and bradyzoites are infective to both definitive and intermediate hosts. The tachyzoites can also cross the placental barrier during pregnancy and infect the fetus. Upon ingestion by definitive host, the parasites enter into the enterocytes and undergo merogony, gametogony and finally produce oocysts that are passed in the faeces. Approximately one third of the population in the world has been infected by *T.gondii* (however, most of the infections remain asymptomatic). Infection in man is acquired either through ingestion of oocyst and bradyzoites or through blood transfusion, abraded skin or wound contamination, and transplacental route. Toxoplasmosis in man may manifest as mild-flue to as severe as fatal toxoplasmic encephalitis including abortion and various other reproductive disorders. Severe disease occurs primarily in immunocompromised subjects. Thus, *Toxoplasma* infections have emerged as one of the major cause of death among AIDS patients. Diagnosis is made mainly by serological tests. However, culture, animal inoculation, and PCR techniques are also available but are either time consuming or expensive.

78. *T. gondii* tachyzoites and *T. gondii* infected macrophage.

79. *T. gondii* tachyzoites (Giemsa stain).

80. Transmission electron microphotograph of *T. gondii* tachyzoite.

81. Scanning electron microphotograph of *T. gondii* tachyzoite.

82. *T. gondii* tissue cyst (Bradyzoites) in brain tissue.

83. Transmission electron microphotograph of *T. gondii* tissue cyst.

84. *T. gondii* oocyst.

85. A case of ocular toxoplasmosis (A well defined scar in retina).

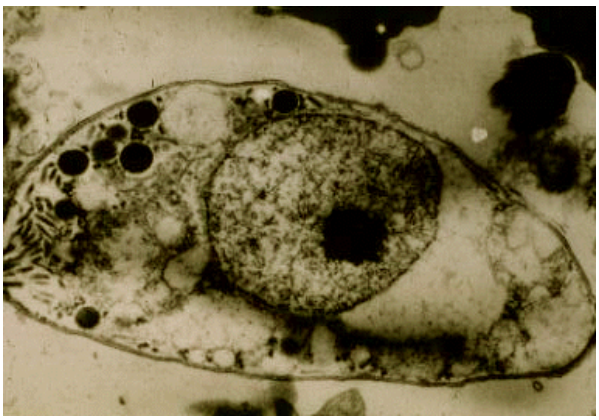

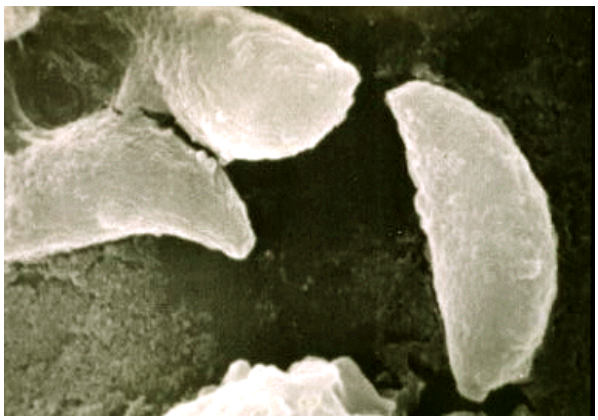

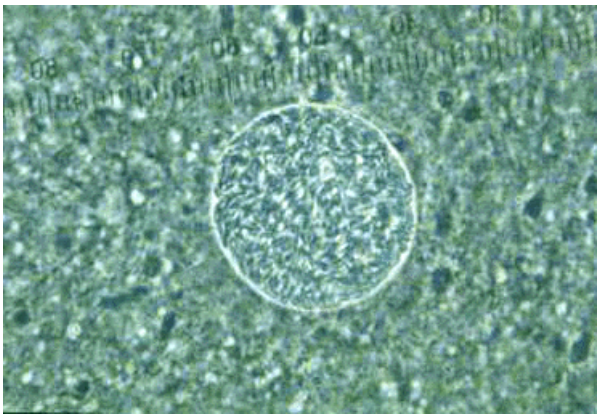

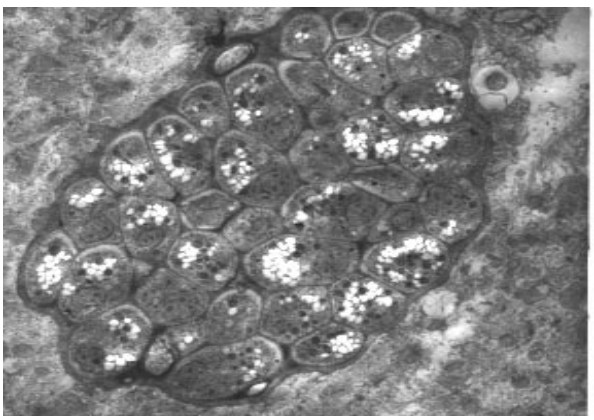

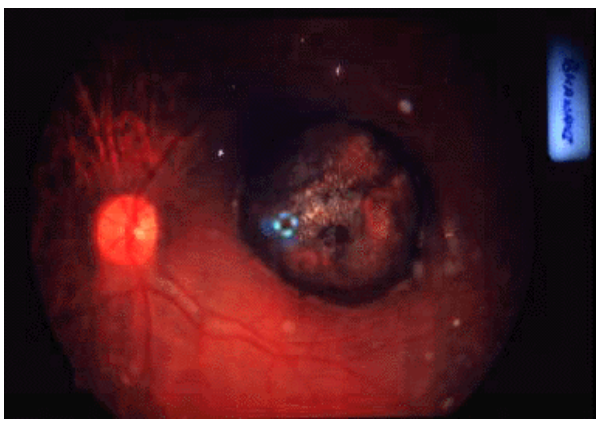

Pneumocystis carinii

(Phylum: Apicomplexa)

P. carinii is a protozoan parasite found in the lung of various mammals including man. It exists in two forms - trophozoite and cyst. The cyst measuring 5-7 µm in diameter contains eight intracystic bodies. The cysts are expectorated in the sputum. Upon inhalation by other susceptible host, sporozoites are released in the lung alveolar space. The sporozoites grow into trophozoites and enter into merogony. Some of the merozoites continue the merogony cycle while the others undergo cyst formation. It is reported from different parts of the world. Infection in man takes place by inhalation of cysts. Infection in man is asymptomatic unless there is a profound T-helper cell disfunction or depression or congenital hypogammaglobulinemia. Thus *P. carinii* is an opportunistic protozoan parasite to cause interstitial pneumonia. Its development correlates well with the blood T-helper cell count of less then 200/cubic milliliter. The typical feature of this parasite is to form a honey comb like alveolar mass containing large number of parasites. Diagnosis is made by detecting the parasites in the sputum, lung aspirate, bronchial washing and lung biopsy materials stained with various staining techniques. *P. carinii* can be cultured on feeder-cell layer (a kind of tissue culture).

86. *P carinii* in lung aspirate smear (Giemsa stain).

87. *P. carinii* in lung aspirate smear (Toluidine blue O stain).

88. Eosinophilic intra-alveolar exudate appearance of *P.carinii* infected lung section (H & E stain).

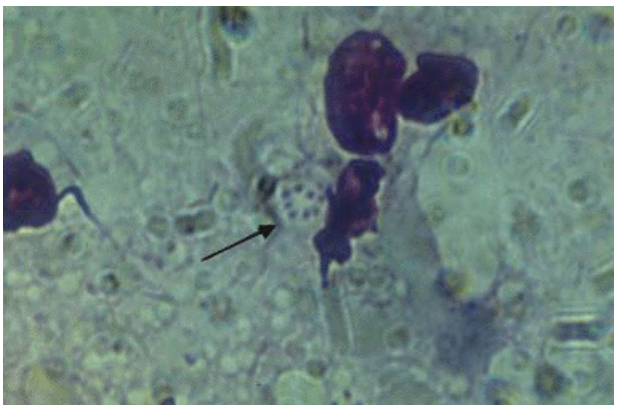

86

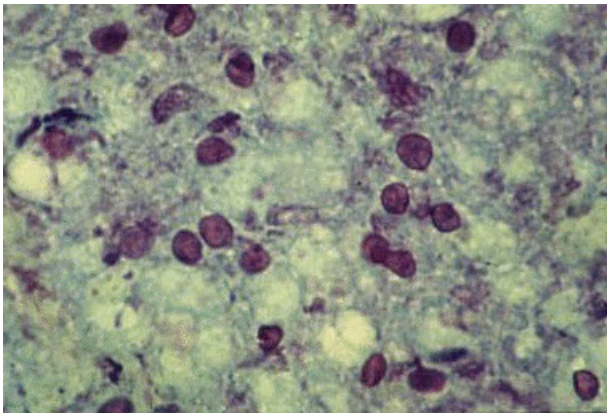

87

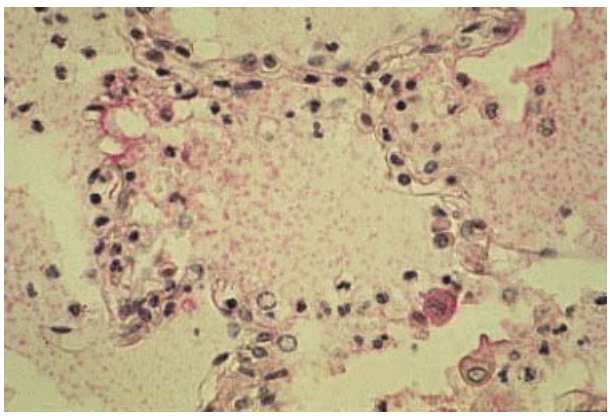

88

Leishmania species

(Phylum: Sarcomastigophora)

Leishmania are the mono-flagellate parasites of reticuloendothial system. It has two forms - cylindrical promastigote form (17 x 3 µm) with a single flagellum (20-30 µm in length) and an ovoid amastigote form (2-4 µm in diameter). It completes its life-cycle in vertebrate hosts and insect host (sand flies of genus Phlebotomus and *Lutzomia*). The amastigote are found in vertebrate host while the promastigotes are found in insect host. There are many species and sub-species of *Leishmania*. The *L. donovani* complex and *L. tropica* complex cause visceral leishmaniasis or kala-azar and cutaneous leishmaniasis or oriental sore, respectively, while the *L. braziliensis* complex and *L. mexicana* complex cause mucocutaneous leishmaniasis or *espundia, uta* and *chiclero* ulcer. Of these, only *L. donovanicomplex* and *L. tropica* complex are found in Old World. The cutaneous leishmaniasis caused by *L. tropica* complex can be both dry or wet types. *L. donovani* complex is most common in Asia. Infection of man occurs through sand fly bite, and through blood transfusion. Kala-azar is characterized by skin depigmentation, fever, spleno-hepatomegaly, anaemia, hypergammaglobulinaemia and emaciation. In India, post-kala-azar dermal leishmanoid (PKDL) also occur in about 20% of cases visceral leishmaniasis. Diagnosis of kala-azar is made either by detecting amastigotes also called L-D (Leishman-Donovan) bodies in the bone marrow, spleen and liver smears, by culturing in NNN (Nicole, Novy, McNeal) medium or by detecting antibodies in serum.

89. *L. donovani* promastigotes (Phase contrast microscopy).

90. *L. donovani* promastigotes (Giemsa stain).

91. *L. donovani* amastigotes (Giemsa stain).

Trypanosoma species

(Phylum: Sarcomastigophora)

Trypanosomes are monoflagellate parasites distributed in West Africa and South America. *T. cruzi* found in South America is transmitted by Reduvid bugs (kissing bugs) while *T. rhodesiense* and *T. gambiense* present in West Africa are transmitted *Glossiua* species. Trypanosomes pass through various stages during their life-cycle in vertebrate and insect host. *T. cruzi* causes Chagas' disease while the African species causes the sleeping sickness. Both Chagas' disease and sleeping sickness are highly fatal. Diagnosis of trypanosomiasis is made by detecting the parasites in blood, bone marrow and cerebrospinal fluid (CSF). Chagas' disease is also diagnosed by means of xenodiagnosis and serological methods.

92. *Trypanosoma* promastigotes in blood smear (Giemsa stain).

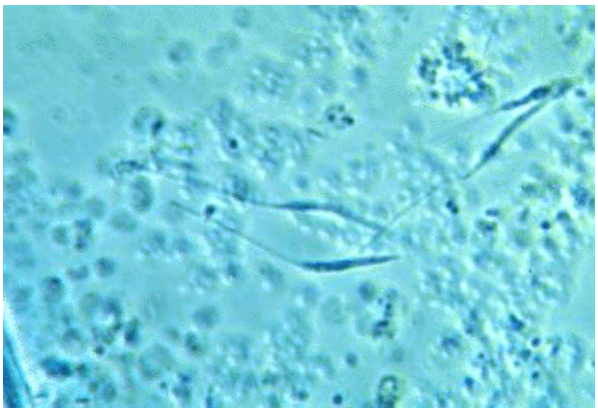

89

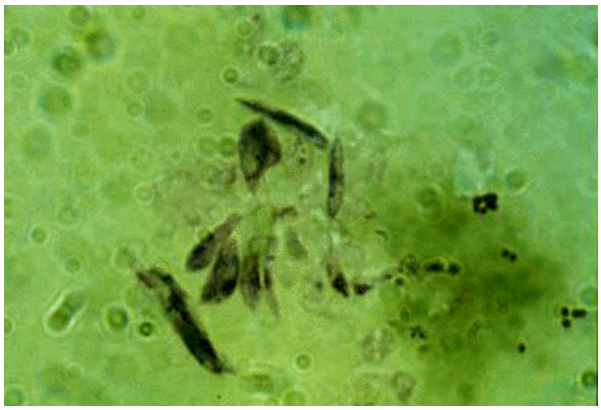

90

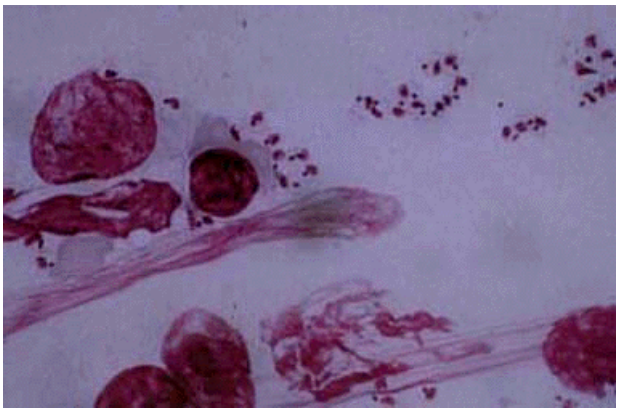

91

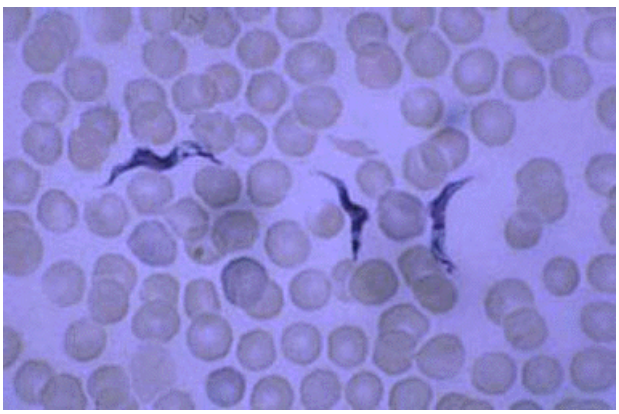

92

Blood and Tissue Helminths

Wuchereria bancro i & Brugia malayi

(Phylum: Nemathelminth)

W. bancrofti and *B. malayi* are distributed in Asia. These worms complete their life-cycle in man (definitive host) and intermediate host (mosquitoes of genus *Anopheles*, *Culex*, *Aedes*, and *Mansonia*). The adult worms are long and slender with smooth cuticles. The male *Wuchereria* measures 40 mm long by 100 µm wide with a finger-like tail. The female is longer than male and measures 6-100 mm in length and 300 µm in width. The adult worms live in the major lymphatic ducts of human and are tightly coiled into nodular masses. The oviparous females produce juveniles called microfilaria with a sheath. Microfilaria when stained, shows several internal nuclei and other organs in it. Characteristically, the tail tip of wuchererial microfilaria does not contain nuclei. In some parts, microfilaria of *W. bancrofti* has a marked nocturnal periodicity in peripheral circulation (maximum numbers of microfilaria are found between 10 PM and 2 AM) while in some other part it does not show such periodicity depending on the feeding habits of the vector. Upon ingestion by the insect host, the microfilaria undergoes various developmental stages and finally reaches to salivary gland of the vector (the L3 Iarva). *B. malayi* show morphological similarity to that of *W. bancrofti* but are smaller (male measures 15-20 mm long by 70-80 µm wide while female measures 80-100 mm long by 250-300 µm wide). Microfilaria of *B. malayi* characteristically contains a single nucleus in the tail tip. These parasites are prevalent in tropical and sub-tropical areas in the world. Infection in man occurs through infective mosqoito bites and causes a disease called filariasis that is characterized by fever, Iymphadenitis, Iymphangitis, hydrocele, elephantiasis, and hypereosinophilia. Diagnosis of filariasis is made by both clinically and by detecting the characteristic microfilaria in the blood taken at appropriate time. Microfilaria, sometimes, can also be detected in urinary deposite. Specific antibodies in the serum using larval antigen can also be done.

93. *W. bancrofi* microfilaria (Giemsa stain).

94. *B. malayi* microfilaria (Giemsa stain).

95. Hydrocoele resulted due to filarial infection.

96. Chyluria (Milky white urine) resulted due to filarial infection (Right).

97. A woman with an elephantiasis ofleft leg.

98. A man with elephantiasis of right leg.

93

94



95



96

97

98

Toxocara species

(Phylum: Nemathelminth)

T canis and *T. cati* are the round worms of dogs and cats, respectively. They are similar to the human round worm but are smaller and characteristically have a prominent cervical alae in both sexes. *T. canis* and *T. cati* adult worms are distinguished by observing the structural difference of the cervical alae (T. cati cervical alae is relatively more wide and striated). The eggs measure about 70-80 µm in diameter are indistinguishable. Infection in dogs and cats takes place by ingestion of embryonated eggs. Human infection takes place in similar way that occurs in dogs and cats. However, the larva can not reach and settle in the intestine as in their definitive hosts. Therefore, the larva keep on migrating in the visceral organs causing severe damage. Hence, the name is visceral larva migrans (VLM). VLM is a syndrome of various clinical manifestations. It is usually characterized by hepatomegaly, persistent hypereosinophilia, bronchial asthma and fever. Infection is more common among children of low socio-economic standards with geophagia or pica. Even in developed countries, the public parks are heavily contaminated with *Toxocara* eggs. Diagnosis of VLM is made by specific antibodies in serum using *Toxocara* embryonated egg antigen or using larval excretory secretary antigen.

99. *Toxocara* larva in fresh liver tissue.

100. *Toxocara* larva in liver tissue (Scaning electron microphotograph).

101. A case ofocular toxocariasis.

l02. *Toxocara* eggs.

103. *Toxocara* eggs (Embryonated).

104. Scanning electron (a, b) and light (c, d) microphotograph of *Toxocara canis* (a, c) and *T. cati (*b, d).

105. *Toxocara* canis adult worm.

106. Cervical alae of *Toxocara.* Relatively narrower and unstriated *T. canis* cervical alae(A) and broad and striated *T. cati* cervical alae(B).

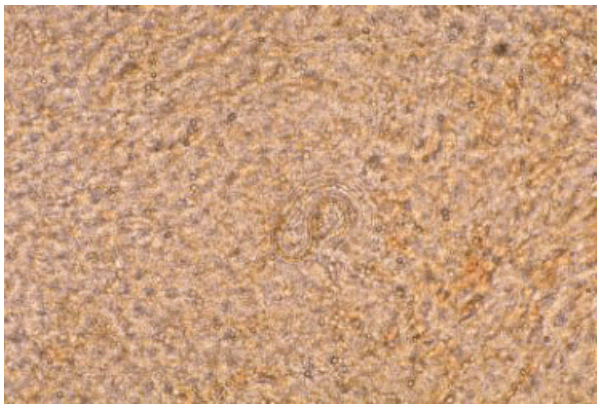

99

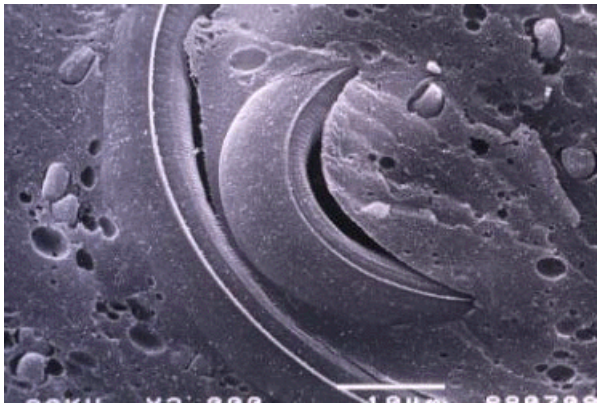

100

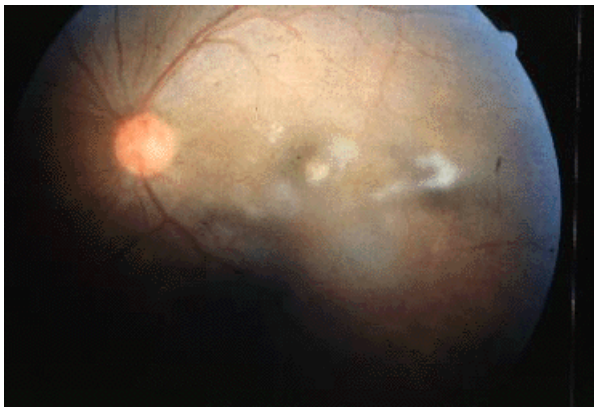

101

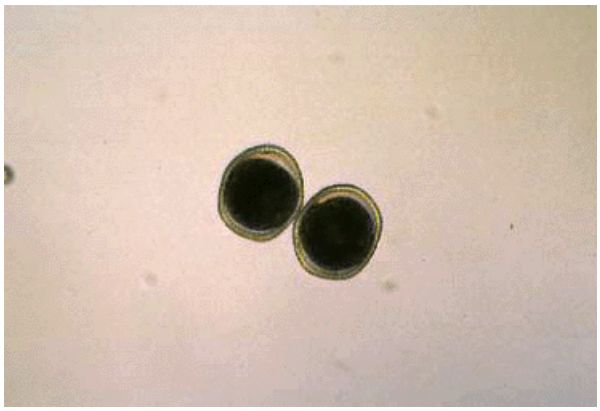

102

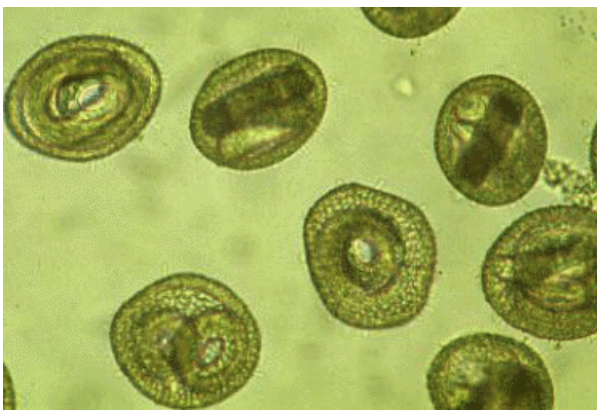

103

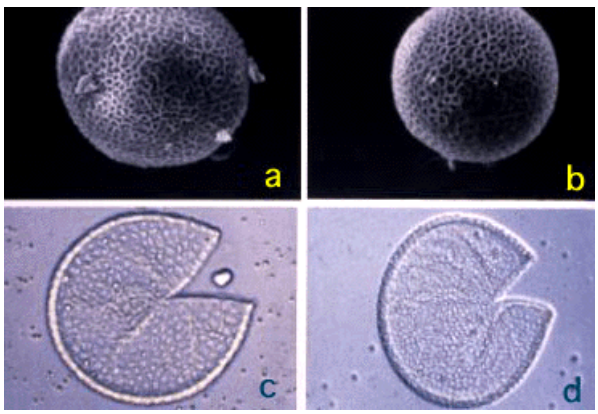

104

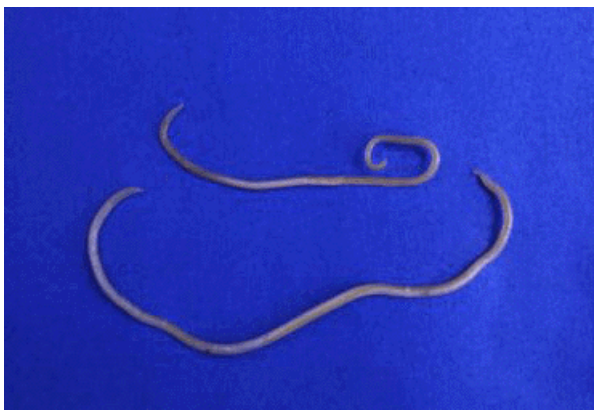

105

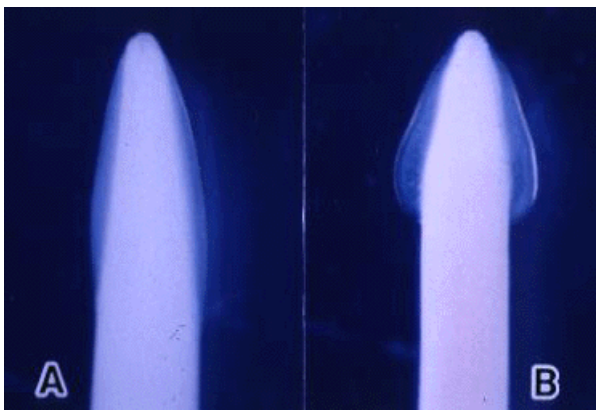

106

Capillaria hepatica

(Phylum: Nemathelminth)

C. hepatica is primarily a parasite of rodents. Morphologically it is very much close to *Trichuris* spp. but not with sudden and obvious demarcation between the anterior filariform portion and the posterior stout form. The female deposits egg (60 x 30 μm in size) in liver parenchyma and remains there until the liver is eaten by predators or until the liver is decomposed after the death of host. The eggs swallowed by the predator host can not cause infection and pass though faeces. Upon reaching to the soil, embryonation takes place and becomes infective. Infection takes place by ingestion of embryonated eggs. The hatched larvae then migrate to the liver where they develop into adult worm. The presence of adult worm and its eggs cause damage of liver cells leading to abnormal liver function. Diagnosis of this parasite infection is difficult. Detection of characteristic eggs in liver biopsy is most reliable. *C. philippinensis* causes violent diarrhoea and is diagnosed by detecting characterisitic eggs in faeces.

107. *C. hepatica* egg.

108. *C. hepatica* eggs in liver (PAS stain).

Angiostrongylus cantonensis

(Phylum: Nemathelminth)

A. cantonensis is a delicate nematode without lips or buccal cavity. The male and female worms measure approximately 17 and 24 mm in length, respectively. In male, the copulatory bursa is small and is without dorsal lobe. The spicules are long and slender. The female appears as the barber-pole due to the intertwining of intestine and uterine tubules. The vulva is about 0.2 mm in front of the anus. The female worms lay eggs in the lung. The hatched larvae crawl up to the trachea and are swallowed, and are finally passed in the faeces. The larva then inters into various types of snail and slug host (the intermediate hosts). The fresh-water shrimp, Iand crab and coconut crab serve as paratenic host. The larva present in the intermediate and paratenic host, when ingested by a definitive host, migrates to the brain and then to the lung where they develop into the adult worm. It is found in tropical areas of the world. Infection of man takes place by ingestion of larvae while eating the intermediate snail hosts (*Achatina fulica*). It causes eosinophilic meningoencephalitis with severe headache and stiffness of neck. The disease is self-limiting. Parasitological diagnosis is diffrcult. Eosinophilic pleocytosis of cerebrospinal fluid and positive immunological diagnosis with the use of A. cantonensis antigens are the methods of diagnosis.

109. *A. cantonensis* larva recovered from snail host.

110. *A. cantonensis* larva in rat intestine.

111. *A. cantonensis* infected rat lung.

112. *A. cantonensis* adult worm showing barbar-pole like colouration.

107

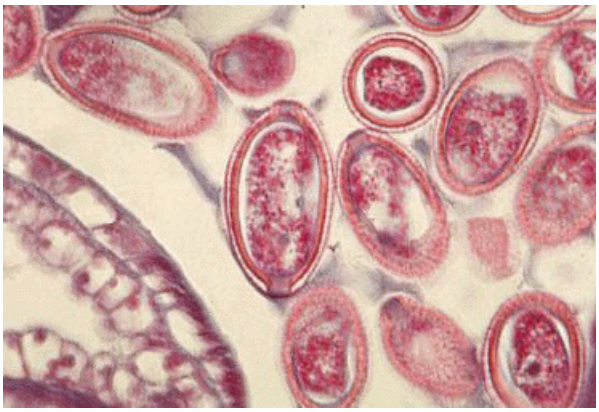

108

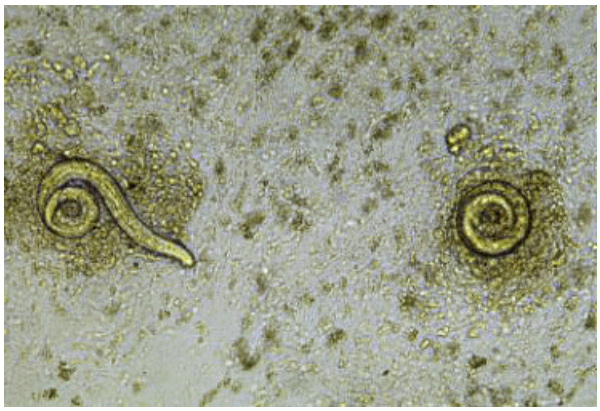

109

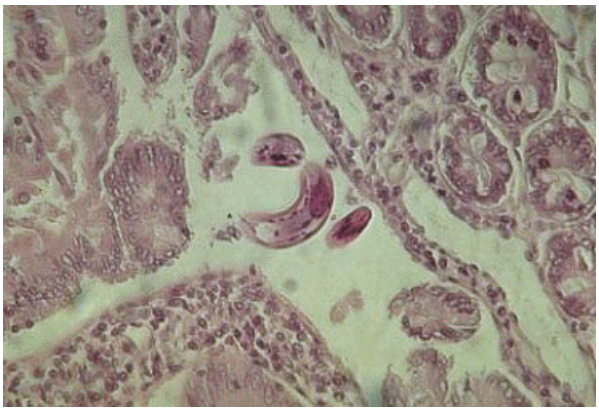

110

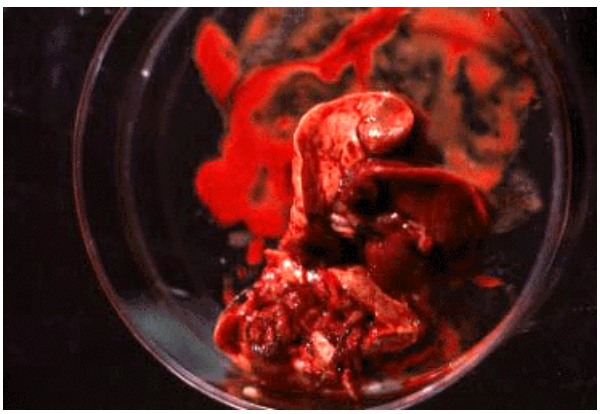

111



112

Trichinella spiralis

(Phylum: Nemathelminth)

T. spiralis is one of the smallest nematode to infect man. Male and female worms measure 1.5 mm and 3.0 mm in length, respectively. The anus is nearly terminal. Copulatory spicule in male is not present and male dies shortly after the copulation. The vulva in female is located nearly at the middle of the oesophagus. The unique aspect of this parasite is that a single animal serves as both definitive and intermediate hosts. Once the infective juveniles are swallowed, they finally grow into adult worm and the fertilized female worms start to give birth ofjuveniles. The juveniles are either passed in the faeces or carried to liver through portal vein. Juveniles carried to liver ultimately reach to the skeletal muscles, particularly of eye, tongue and diaphragm, where they are encysted. *T. spiralis* can infect most of the mammals. Thus, both sylvatic and domestic cycles of trichinosis can occur. *T. spiralis* infection is not so common in developing countries. Human infection takes place by ingestion of encysted juvenile present in raw or undercooked meat. The disease is characterized by various types of signs and symptoms depending on the stages of the parasite. The adult worm in intestine causes acute food poisoning like symptoms. The migrating larvae cause muscular pain and muscular paralysis in extremities, and the larvae undergoing encystment cause severe toxaemia like symptoms. Diagnosis is made by detecting encysted larvae in biopsied or autopsied tissues but not always practicable. Thus, several immunodiagnostic tests have been developed. Besides, xenodiagnostic technique by feeding suspected biopsied material to laboratory rats also is employed.

113. *T. spiralis* larvae in tissue section.

114. *T. spiralis* larvae recovered from tissue.

Anisakis species

(Phylum: Nemathelminth) ,

Anisakis is a round worm of marine mammals such as whales, dolphins and porpoises. The larval forms are found in various types of fishes. The infective larvae are thin, slender and measures about 1.5-2.5 cm in length and 0.1 cm in diameter. The outer surface is somewhat striated and there is a ventriculus between the oes h op agus and the intestine. Infection takes place while consuming raw fish particularly the herrings and others. It is reported from Scandinavian countries and Japan. In man, it causes intestinal colic, fever and intestinal obstruction. Parasitological diagnosis of stomach anisakiasis can be made only by endoscopic observation of parasite, and by eating history of intermediate host, while the diagnosis of intestinal anisakiasis can be made immunologically by using monoclonal antibody.

115. Cross section of *Anisakis* in stomach section (H & E stain).

116. Infective stage *Anisakis* larva recovered from fish.

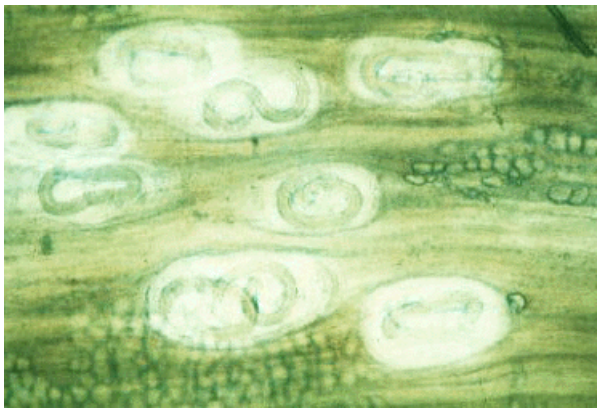

133

134

135

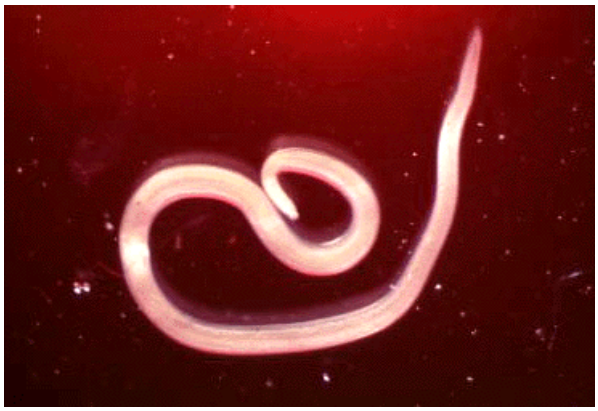

136

Gnathostoma spinigerum

(Phylum: Nemathelminth)

G. spinigerum is a pink coloured stout worm found in felines. The swollen head bulb is covered with four circles of stout spines. The male and female worms measure 1-3 cm and 2-5 cm in length, respectively. Spicules in male are simple with blunt tips. The vulva in female is slightly towards the posterior from the middle of the body. The eggs are oval in shape, measure 70 x 40 µm in size, and are unembryonated when laid. The larva hatched in water enter into the copepod (the first intermediate host) and subsequently into the fish or frog (the second intermediate host). Inside the second intermediate host, they live in connective tissues. From second intermediate host, it is also spreaded into snakes, birds, and other mammals. Human infection takes place while eating raw or undercooked' fishes containing third-stage larvae. In man, it causes both gnathostomiaisis interna (vomiting, urticaria and eosinophilia with cutaneous eruption) and gnathostomiasis externa (migrating intermittent subcutaneous oedema persisting as long as for ten years). Besides, cerebral and ocular gnathostomiasis also occur. Diagnosis is made by identifying the migrating larva in biopsied tissues and by skin test using larval or adult *Gnathostoma* antigen.

117. *G. spinigerum* eggs.

118. *G. spinigerum* larva.

Spirometra erinacei

(Phylum: Platyhelminth)

Sparganum is a plerocercoid larval stage of various species of *Spirometra*. The adult worm is similar to *D. Iatum* and is found in canine and feline hosts. The procercoid larvae are found in fresh-water cyclops and plerocercoid larva in frogs, snakes, and man. Canine hosts are infected while eating frogs and snakes. Infection in man takes place through ingestion of procercoid containing cyclopes or by eating raw frogs or snakes or other mammals or by Chinese customs of rubbing raw frogs in the eyes or ulcers. Sparganum in man can be found in many parts of the body. The sparganosis is characterized by painful swelling. The sparganum measures 8-32 cm x 0.5-1.5 mm in size. Death of parasite causes intense inflammatory reaction with eosinophilic infiltration. Diagnosis is made by detecting the sparganum in surgically removed painful mass.

119. Sparganum (*S. erinacei* larva) in tissue.

120. Sparganum recovered from tissue.

121. Anterior end of sparganum.

122. Posterior end of sparganum.

123. Scolex of *S. erinacei* (Under ligh microscope).

124. Scolex of *S. erinacei* (Scaning electron microphotograph).

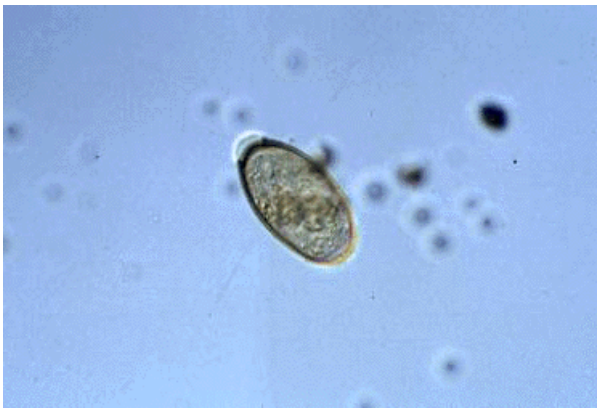

117

118

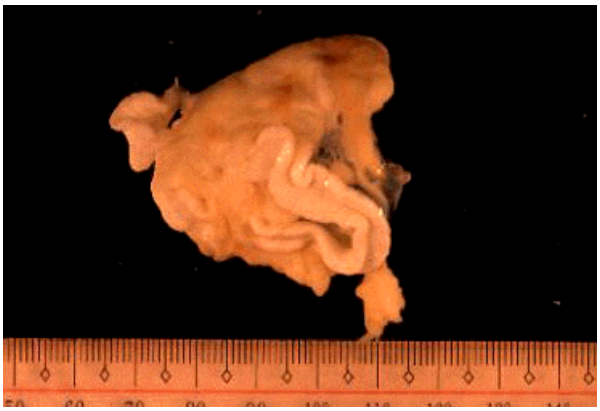

119

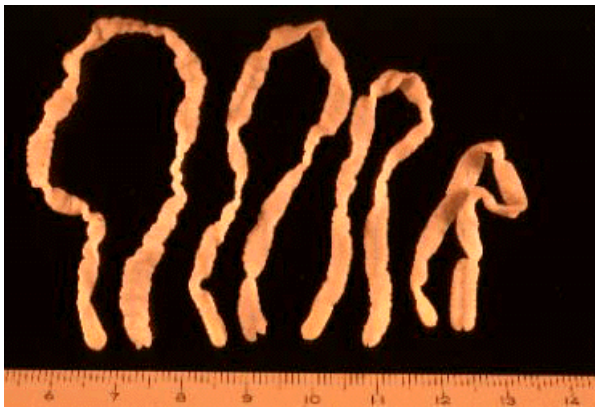

120

121

122

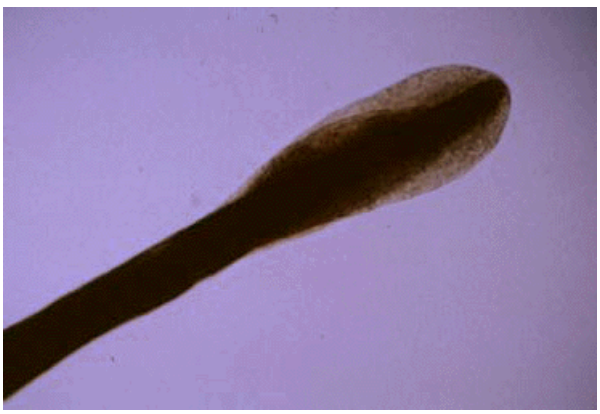

123

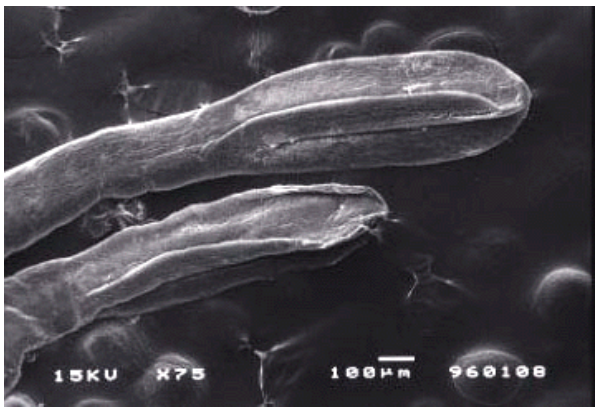

124

Echinococcus granulosus

(Phylum. Platyhelminth)

E. granulosus is a tapeworm of dogs. The adult worm is short measuring 3-6 mm in length and consists of head with double rows of hook, short neck and usually only three segments, the terminal segment being half of the total body length. The adult worms live in the small intestine of the definitive host (dogs and other canine host). The eggs passed in the faeces of definitive hosts are identical to those of Taenia spp. The eggs are infective to various animals including man. Sheep are the most suitable intermediate host for this parasite. Inside the intermediate host, it slowly develops into a hydatid cyst containing numerous protoscoleces infective to the definitive hosts. The most common site for the development of hydatid cyst is the liver followed by lung and other organs including the brain. Infection in man takes place by ingestion of eggs. The clinical manifestation does not appear until the size of cyst is not sufficiently big enough. The type and extent of clinical manifestations depend on the location of the cyst in the body. The most common site for hydatid cyst is liver (50%) followed by lung (40%) and others (10%). Rupture of cyst cause anaphylactic shock. Hydatidosis is serious problem in many parts of the world particularly in sheep raising areas. Diagnosis of hydatidosis in man is made by Casoni's test, by detecting protoscoleces in hydatid cyst fluid, or by detecting antibodies to cyst fluid antigen.

125. Surgical removal of hydatid cyst (Unilocular) from liver.

126. Hydatid cyst after draining of cyst fluid.

127. Protoscoleces of *E. granulosus* in hydatid sand.

128. Section of hydatid cyst wall (H & E stain).

129. *E. granulosus* adult worm.

Echinococcus multilocularis

(Phylum: Platyhelminth)

E. multilocularis is smaller (1.5-3.0 mm) than *E. granulosus*. The uterus does not have lateral branches. Its natural life-cycle is sylvatic where foxes act as definitive host. The cyst is multilocular and metastatic. Infection in man takes place by ingestion of eggs. Parasitological diagnosis is difficult as protoscoleces are found rarely.

130. Protoscoleces of *E. multilocularis* in hydatid sand (Found rarely).

131. Multilocular hydatid cyst in lung (Metastatic nature).

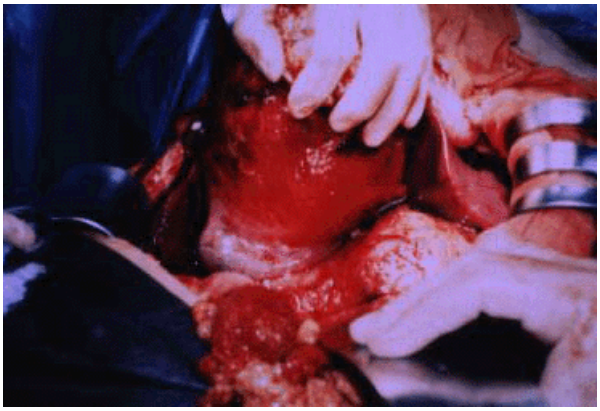

125

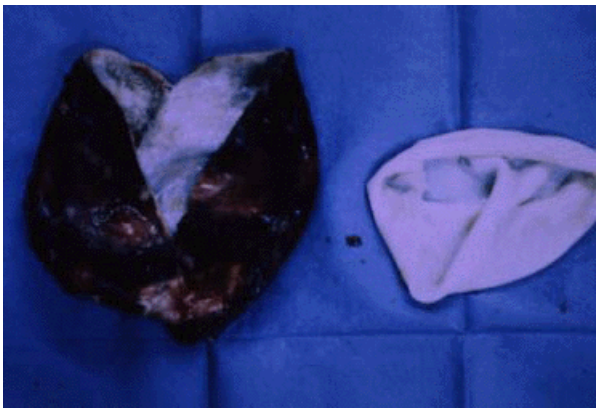

126

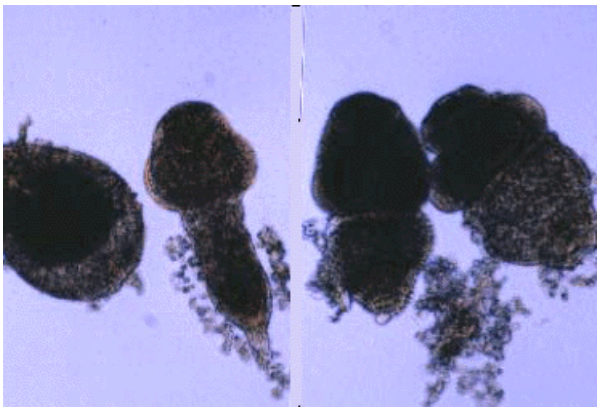

127

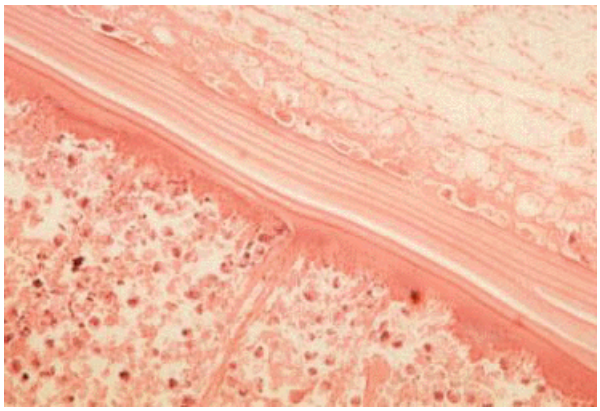

128

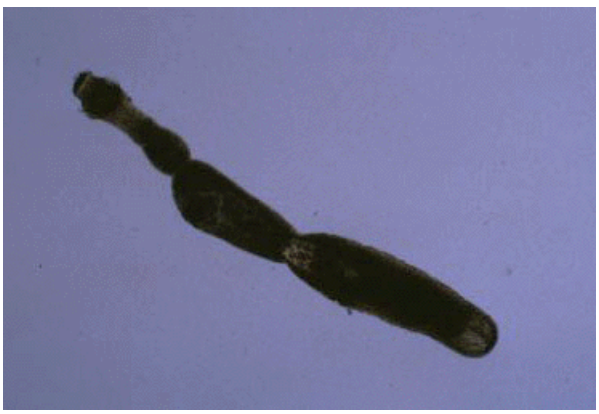

129

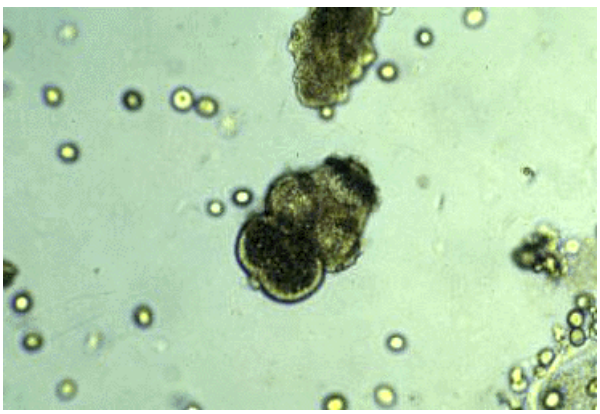

130

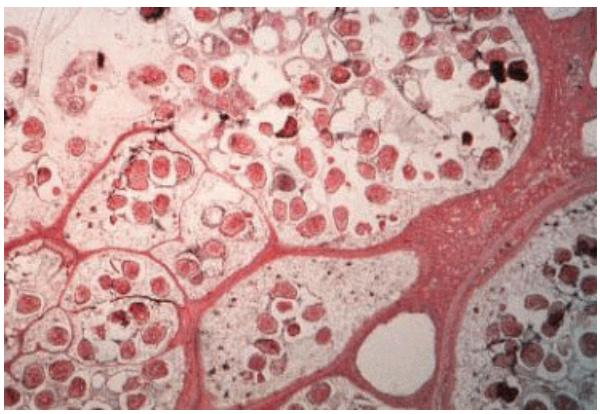

131

Paragonimus westermani

(Phylum: Platyhelminth)

P. westermani is mainly found in crab eating areas in the world. The life-cycle is completed in three different hosts, the man, the snail (Thieridae family), and the crabs and cray fish. The adult worm living in human lung are thick, reddish-brown and measure 8-12 mm in length and 4-6 mm at the greatest width. The oral and ventral suckers are about equal in size. The eggs are operculated and measure 80-120 x 50-60 µm in size. In the water, the miracidium hatched from egg enter into a snail host and undergo sporocyst, redia and finally a cercaria formation. The cercaria are microcerous with knob-like tail and a small oral stylet. Upon entering into the crabs or cray fishes, they are encysted in the viscera and muscles (metacercaria). Wild boar is known to serve as paratenic host for *P. westermani*. Human infection takes place by ingestion of metacercaria present in raw or undercooked crabs, cray fishes, and wild boar meat. The parasite excyst in the duodenum, penetrate the intestinal wall and proceed to the lung by penetrating the diaphragm. In the lung, it causes the chest symptoms resembling the pulmonary tuberculosis (endemic haemoptosis). Besides the pulmonary symptoms, it may also cause other ectopic manifestations. Diagnosis is made either by detecting characteristic eggs in the sputum, bronchial washing, aspirated pleural fluid or in the faeces. For ectopic infection serological method is more useful.

132. *P. westermani* adultworm recovered from lung.

133. *P. westermani* adult worm (Carmine stain).

134. *P. westermani* egg.

135. *P. westermani* infected lung.

136. *P westermani* metacercaria recovered from crab.

137. Metacercaria containing crab (Second intermediate host).

Paragonimus miyazakii

(Phylum: Platyhelminth)

P. miyazakii resembles *P. westermani*. It is relatively more elongated than *P. westermani* and the uterus is profusely branched. The mode of infection, pathogenesis and diagnostic methods are similar to that of *P. westermani*.

138. *P. miyazakii* adult worm (Carmine stain).

139. *P. miyazakii* egg.

132

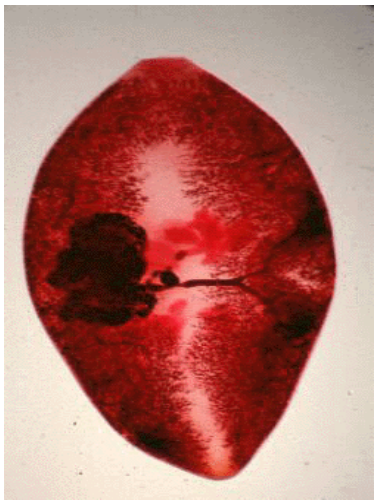

133

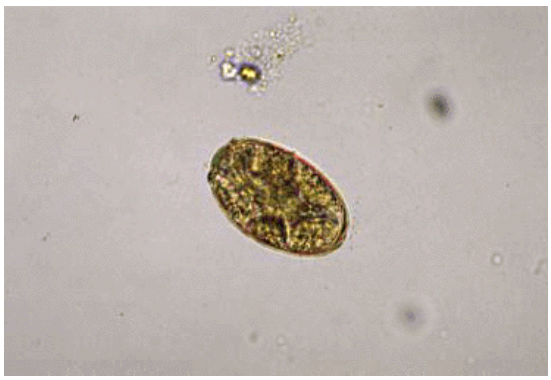

134

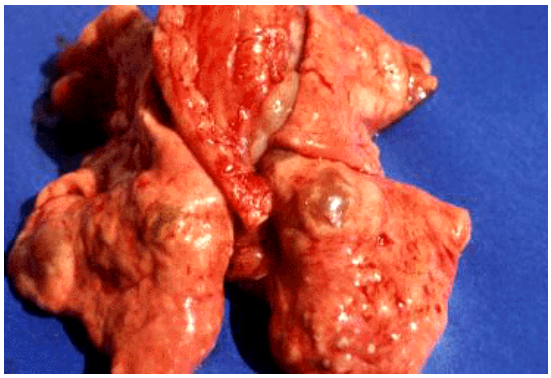

135

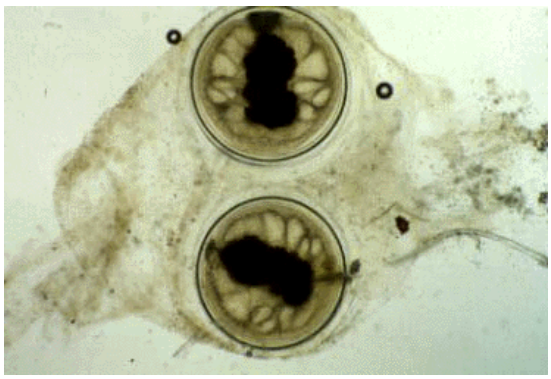

136

137

138

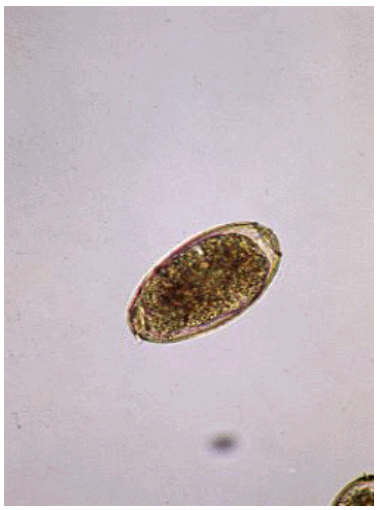

139

Schistosoma species

(Phylum: Platyhelminth)

S. japonicum, *S. haematobium*, and *S. mansoni* are the three species of Schistosoma of medical importance. The male has a ventral gynacophoric canal inside which the female normally live. The females are thin and longer than males. The three species of the Schistosoma are differentiated on the basis of their size, tegumental papillae, number of testes, position of ovary in female worm and the size, shape and type of spine of eggs. Schistosoma completes its life-cycle in human and snail hosts of different genus depending on the species of Schistosoma. Briefly, the eggs in the water

Characteristics	*S. haematobium*	*S. mansoni*	*S. japonicum*
Size			
Male	10-15 mm	10-15 mm	12-20 mm
Female	20mm	20mm	26 mm
Tegumental papillae	Small tubercles	Large with spines	Smooth
Number of testes	4 to 5	6 to 9	7
Position of ovary	Near mid body	In anterior half	Posterior to mid body
Eggs			
Size	145 x 55 μm	147 x 56 μm	85 x 60 μm
Shape	Elliptical	Elliptical	Oval or round
Spine	Sharp & terminal	Sharp & Iateral	Rudimentary & Iateral
Found in	Urine	Stool	Stool

give rise to a free swimming miracidium which enters into the specific snail host and undergoes sequential developmental process finally giving rise to an infective schistosomulae. These parasites have certain endemic foci of infection. Human infection takes place when the schistosomula penetrates the skin while swimming, irrigating the rice field, washing cloths or while ablution. In man, it causes abdominal pain, diarrhoea with blood and mucus in case of S. mansoni and S. japonicun. On the other hand, S. haematobium causes haematuria, cystitis and burning sensation while urination. Of these, infection with S. japonicum is most grave. Diagnosis is made by detecting characteristic eggs in respective samples (urine samples for S. haematobium and stool samples for S. mansoni and S. japonicum) and by immunological methods.

140. *S. mansoni* egg with lateral spine.

141. *S. haematobium* egg with terminal spine.

142. *S. japonicum* egg with lateral knob.

143. *S. mansoni* adult worm (Scanning electron microphotograph).

144. *S. japonicum* adult worm (Scanning electron microphotograph).

145. Cercaria penetrating the skin.

146. Result of cercumoval precipitation test.

147. *Schistosoma* egg granuloma in liver.

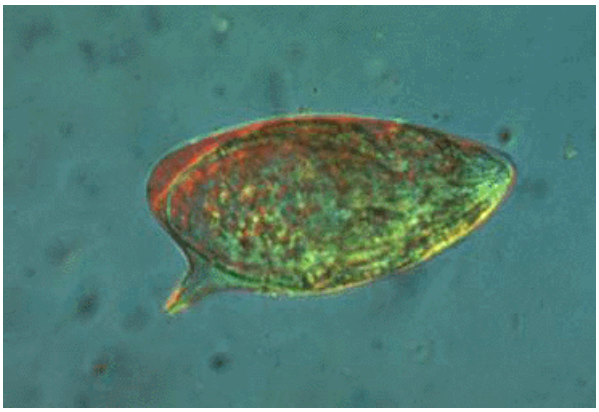

140

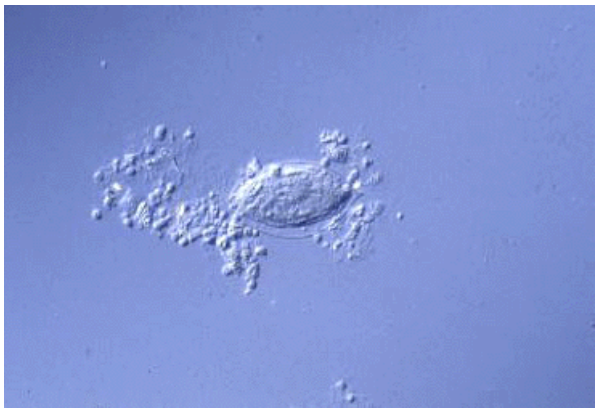

141

142

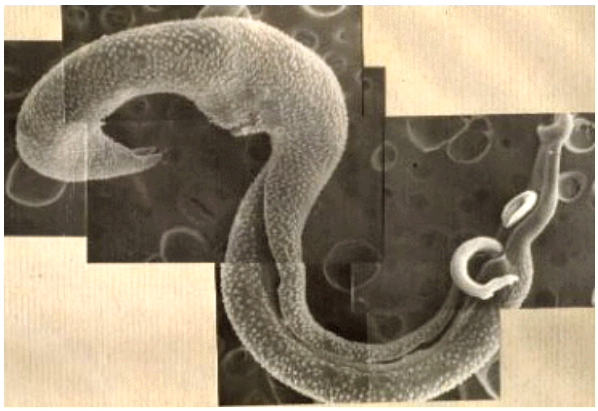

143

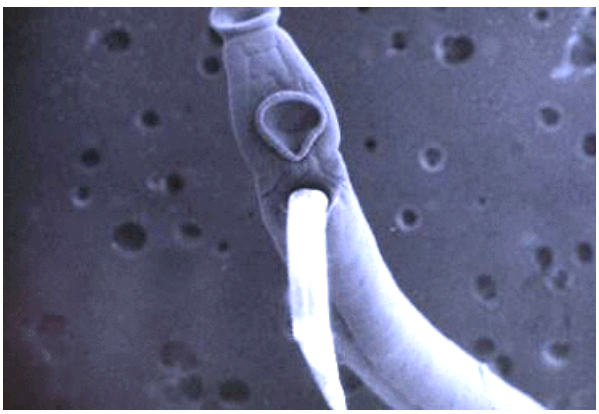

144

145

146

147

Clonorchis sinensis

(Phylum: Platyhelminth)

C. sinensis is a common parasite of man and other mammals. It is spatulate in shape and tapered anteriorly. It measures 10-25 x 2-5 mm in size. The oral sucker is bigger than ventral sucker. The eggs are yellowish-brown in colour, operculated and measure 25 x 16 µm in size. There is a small knob like projection at non-operculated end of egg. Miracidium is hatched only after entering the snail host. The cercaria has a long tail with dorsal and ventral fins. Cercaria then enters into the fish by penetrating the skin and forms metacercaria. Infection in definitive host takes place by ingestion of metacercaria present in raw and undercooked fish or crustaceans. It causes recurrent attacks of cholangitis with fever, chills and jaundice. It also causes pancreatitis. It is mainly found in orient. Diagnosis is made by detecting characteristic eggs in faeces and aspirated bile samples.

148. *C. sinensis* adult worm (Carmine stain).

149. *C. sinensis* eggs.

Metagonimus yokogawai

(Phylum: Platyhelminth)

M. yokogawai is a smallest fluke to infect man and other mammals such as cat, dog and pig. It measures about 1.0 x 0.5 mm in size and live in the small intestine of definitive host. The ventral sucker is characteristically deflected to the right with its long axis in the diagonal plane. The egg measures 27 x 16 µm in size and resemble that of *C. sinensis.* The moluscs and fish (*Plecoglossus*) are the first and second intermediate hosts, respectively. The cercaria has a lateral fluting tail. It is found in Japan and Russia. Infection in definitive host takes place by ingestion of metacercaria present in raw or undercooked fish. It causes a catarrhal condition of intestine and diarrhoea.

150. *M. yokogawai* adult worm (Carmine stain).

151. *M. yokogawai* egg.

152. Fish (sweetfish) that contain *M. yokogawai* metacercaria.

148

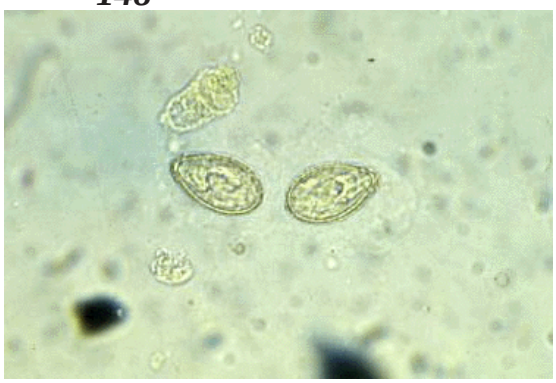

149

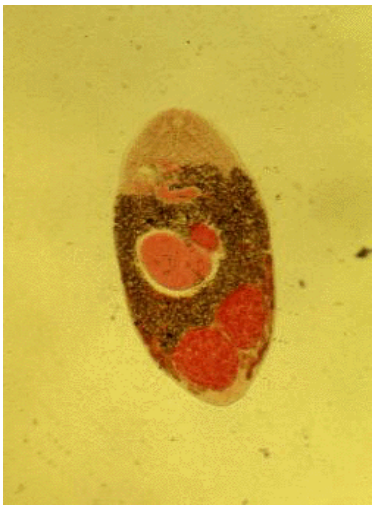

150

151

152

Heterophyes heterophyes

(Phylum: Platyhelminth)

H. heterophyes is a small fluke measuring about 1.5 x 0.4 mm in size. The entire body is covered with slender scales. The ventral sucker is bigger (more than double in size) than oral sucker (90 µm in diameter) and is located at the end of one third of the body. The eggs are 25 x 16 µm in size and contain fully developed miracidium. The adult worm lives in the small intestine burrowed between the villi. The miracidium hatched in water enters into the barkish-water snail host and undergoes further development. The cercaria emerged from snail enter into the fishes by penetrating the skin where they metamorphosed into metacercaria. Infection in definitive host takes place by ingestion of metacercaria present in raw or undercooked fishes (*Mugil*, *Gambusia* and *Acanthogobius*). Fish-eating mammals such as cats, dogs, foxes serve as natural reservoirs of infection. It causes diarrhoea. Diagnosis is difficult unless the adult worm is not available as the eggs are very much identical to the eggs of *Metagonimus* sp..

153. *H. heterophyes* egg.

154. Scanning electron microphotograph of different parts of the *H. heterophyes* adult worm (1-3: Ventral surface view; 4: Oral sucker; 5: Posterior end; 6: Gonotyl, and 7 and 8: Chitineous rodlets) and eggs.

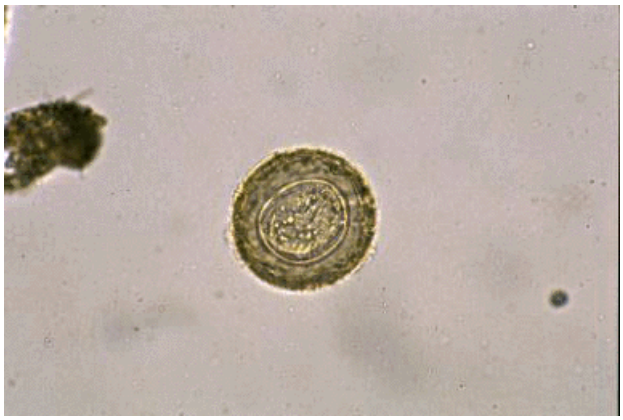

153

Heterophyes heterophyes

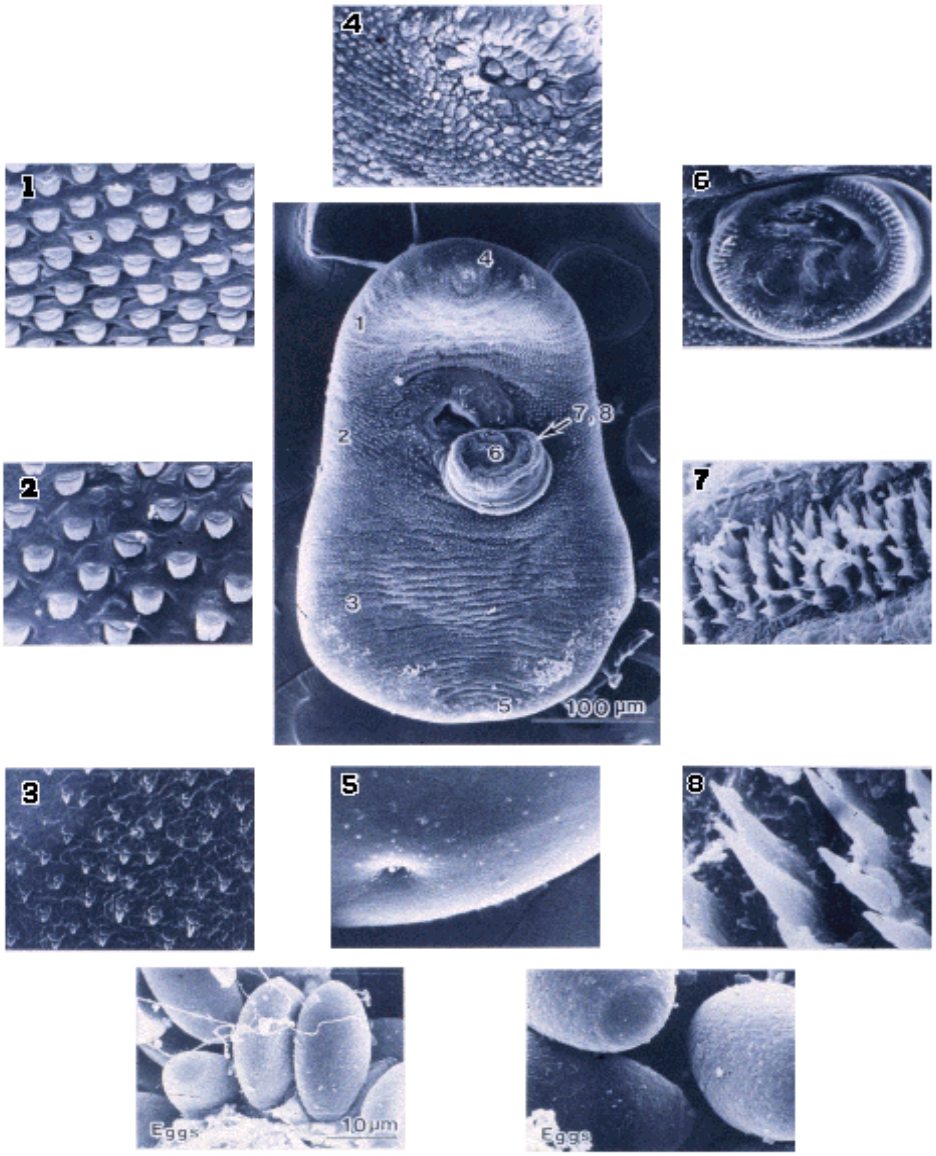

Fasciola species

(Phylum: Platyhelminth)

Fasciola spp. are leaf-shaped chocolate-brown colour parasite. In nature it completes its life-cycle in sheep (definitive host) and snail host (intermediate host). The oral sucker is small but powerful and is located at the end of a cone shaped projection of anterior end. The ventral sucker is bigger than oral sucker and quite anterior almost at the level of shoulders. The cone and the ventral sucker are the important characteristic features for identification. The eggs are oval in shape, measure 140 x 70 µm in size and are operculated. The adult worms live in the bile duct and eggs laid in the bile duct are ultimately passed in the faeces. In the water, a miracidium hatched from egg enters into the snail host and undergoes further development. The cercaria (with club shaped tail) comming out from snail host then attach to any available object (aquatic vegetation) and transform into metacercaria shedding off the tail. Mammals are infected while grazing on aquatic vegetation. The larva excysted in the intestine then proceeds to liver by penetrating the intestinal wall and then liver capsule. Infection in man takes place by ingestion of metacercaria while chewing metacercaria containing aquatic vegetations. Infection in man causes liver symptoms with fever and cramp-like pain in the right subcostal region. The migrating larva also causes cutaneous fasciolopsis. Diagnosis is made by detecting the characteristic eggs in faecal samples. Immuno-serological methods are also useful.

155. *Fasciola* sp. adult worm.

156. *Fasciola* sp. eggs.

155

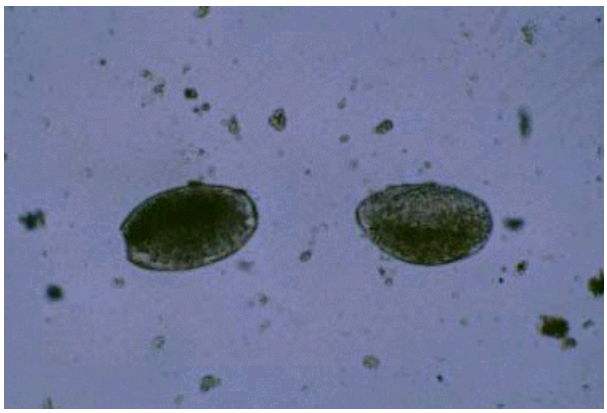

156

Others: Ectoparasites

Sarcoptes scabiei

(Phylum: Arthropoda)

This is one of the important ectoparasite of man in tropical and sub-tropical areas. The male and female S. scabiei measure 0.2 mm and 0.4 mm, respectively. They have legs, suckers (ambulata) and number of spines and conical scales on dorsal surface. The greater part of the females is covered with fine transverse folds. The gravid females lay their eggs in a burrow in the skin. The eggs are oval and measures about 150 x 100 µm in size. Eggs may give rise to adults in about two week's time passing through larval and nymphal stages. Infection in man is acquired through close contact, and is one of the sexually transmitted disease in man. It is more common in children. It is characterized first by small, raised and reddish track with intense itching. Later, it forms papules, then vesicles that ruptures and encrusts serum. The most often involved parts in the body are the skin between fingers, the breasts, the shoulder blades, the penis, and the creases of knees and elbows. It has several names such as scabies, Norwegian itch, and seven year itch. Morphologically similar parasites cause scabies in animals.

157. S. scabiei.

158. Scabies of hand.

159. Higher magnification of scabies of hand.

Lice

(Phylum: Arthropoda)

There are three types of lice infecting human beings namely *Pediculus humanus humanus* (body lice), *P. humanus* capitis (head lice), and *Phthirus pubis* (pubic lice). The body lice and head lice are indistinguishable morphologically. The body can be divided into head, thorax, and abdomen. They are dorsoventrally flattened and can be easily seen by naked eyes (males and females measuring 2 mm and 3 mm, respectively). The whole life-cycle is completed in human host. The body louse is more common in cooler areas of the world while in tropical areas where people use few clothes usually have only head lice. The *P. pubis* is usually found on hairs of genital region. It is somewhat shorter and broader than *Pediculus* measuring up to 2 mm in length. In general, the pubic lice look like a crab. Hence, it is also called crab-lice. These parasite suck the human blood. They also cause dermatitis. Moreover, Iouse also acts as the vector for *Rickettsia prowazekii* causing typhus fever and *Borrelia recurrentis* causing relapsing fever.

160. Pubic lice.

161. Lice eggs on the hair.

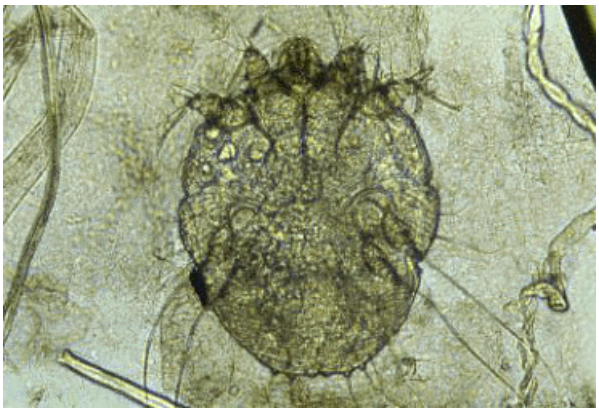

157

158

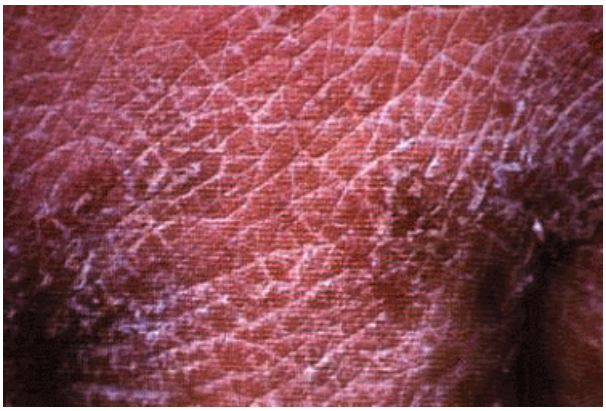

159

160

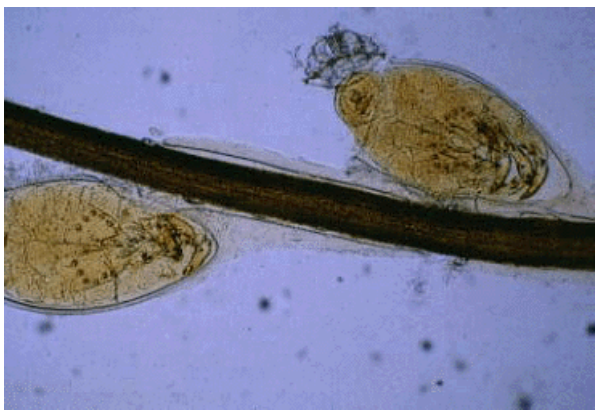

161

Flea

(Phylum: Arthropoda)

Fleas are the laterally compressed ectoparasites composed by blunt head, compact thorax and a relatively large rounded abdomen. The body colour is usually dark-brown. There are many types of fleas belonging to various genera namely *Pulex, Xenopsylla, Echidnophaga, Tunga, Ctenocephalides, Nosopsyllus,* and *Leptopsylla.* Fleas are commonly found in tropical areas and infest various types of mammals including human beings. Fleas are very good jumper and can jump more than hundred times of its body length. The life cycle is not completed in the host as in the case of lice. The eggs deposited on the body are not sticky and fall down in the environment where they undergo further development to become the adult fleas. Fleas feed on host blood and cause irritation, nuisance, and localized dermatitis at the site of bite. Fleas are also important vector of various diseases including deadly plague. The various diseases transmitted by fleas includes plague, typhus, brucellosis, tularemia, melioidosis, dipylidiasis and hymenolepsiasis.

162. Flea (Female).

163. Flea (Male).

164. Flea bite skin lesions of legs and hand.

Dermatobia hominis

(Phylum: Arthropoda)

D. hominis is a human skin bot. It is a forest inhabitating fly found in Mexico and most parts of the South America. It develops in the skin of almost any warm blooded animals, including birds. The adult fly deposit eggs on the abdomen of blood sucking or sweat lapping flies, mosquitoes or tick which in turn distributes the eggs while sucking their blood meal. The eggs then hatch and the young larva bore through t he skin. In human, it causes painful skin lesions (myiasis). A small incision in the skin exposes the larva. It has characteristic two projections at the posterior end.

165. *D. hominis* third-stage larava obtained from skin-lesion.

166. Skin lesion at the upper arm.

167. Skin lesion at the eye lid.



162

163

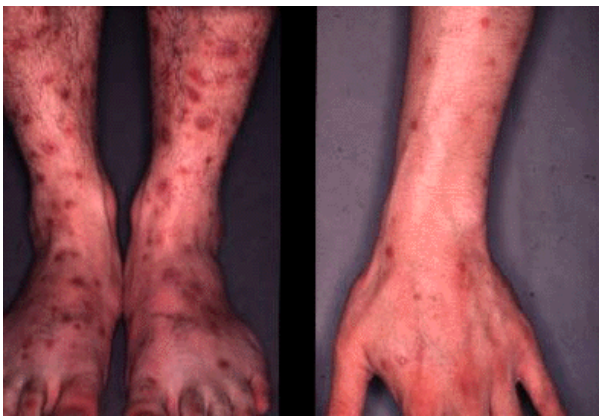

164

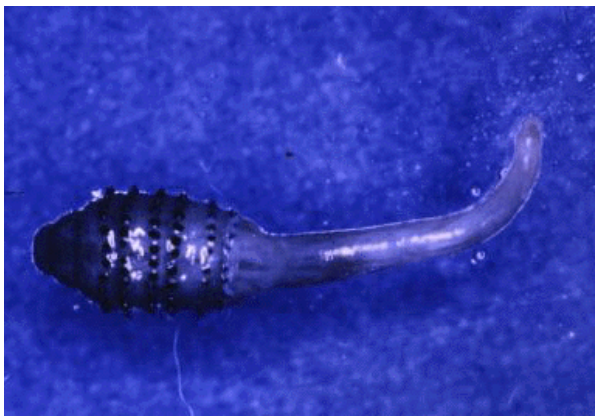

165

166

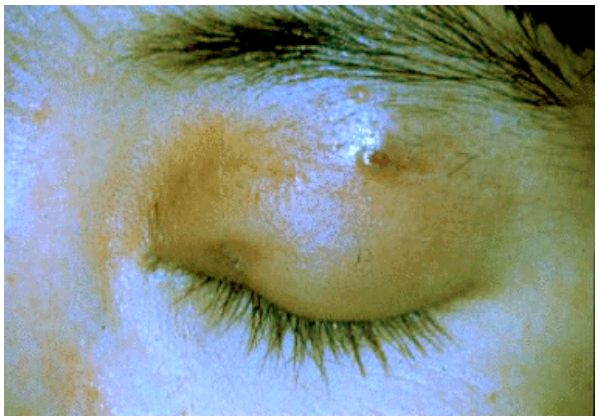

167